

Onychodystrophy and its management

Management der Onychodystrophie

Abstract

Onychodystrophy represents various pathologic processes of the nails such as infectious and noninfectious disorders including onychomycosis, psoriasis and allergic and irritant dermatitis. Nail changes may also be a clue to other dermatological or systemic diseases. But often it is difficult to establish the diagnosis as most nail changes are unspecific. The purpose of this article is to give an overview of the anatomy of the nail organ and possible causes of onychodystrophy. Therapeutic modalities are reviewed as well as modes of analysis.

Zusammenfassung

Onychodystrophien repräsentieren verschiedene pathologische Prozesse des Nagels wie beispielsweise infektiöse und nichtinfektiöse Erkrankungen einschließlich der Onychomykose, Psoriasis und der allergischen und irritativen Kontaktdermatitis. Nagelveränderungen können darüber hinaus Hinweise für andere dermatologische oder innere Erkrankungen geben. Häufig ist es jedoch schwierig, die Diagnose zu stellen, da die meisten Nagelveränderungen unspezifisch sind. Gegenstand dieses Artikels ist es, einen Überblick über die Anatomie des Nagelorgans und mögliche Ursachen der Onychodystrophie zu geben. Therapiemodalitäten werden ebenso kritisch gewürdigt wie Untersuchungsmethoden.

Text

Anatomy and physiology of the nail organ

The human nail (unguis, onyx = nail), the horny covering of the upper surface of the tip of each finger and toe, is a set of complex structures that can most accurately be called the nail unit. The nail unit is an entire organ consisting of the nail matrix, the nail plate, the nail bed and the nail folds (Figure 1), [1], [2], [3]. The nail plate, the final product of the nail unit, is a hard, relatively inflexible multilayered sheet of cornified cells, usually between 0.5-0.7 mm in thickness. Histologically, the nail plate is formed by flattened onychocytes, derived from the cells of the keratogenous zone of the matrix. The onychocytes are, for the most part, anucleated and are smaller on the surface than on the bottom of the plate. The product of these cells is onychokeratin. The nail plate is resting on the nail bed being firmly attached. The nail bed consists of barely proliferating, stratified cells that exhibit no mitoses and keratinize very gradually throughout most of the extension of the bed. Approximately one fourth of the nail is covered by the proximal nail fold while a small margin of the sides of the nail plate is often occluded by the lateral nail folds. Some authors term the lateral nail fold and adjacent finger tissue lateral to the nail fold the nail wall [1], [4].

Tilmann Oppel¹
Hans Christian Korting¹

¹ Department of Dermatology
and Allergology, Ludwig-
Maximilians-University,
Munich, Germany

The nature of onychodystrophy

Abnormal nails can be caused by a huge variety of underlying diseases (Figure 2) such as fungal and nonfungal infections, various noninfectious inflammatory dermatologic diseases of the nail unit and tumors. Changes in nails can also be a sign of systemic diseases, they can occur secondarily to systemic drug use and many other rare or ill defined factors [5], [6]. Abnormal nails in a stricter sense as a rule represent changes of the nail plate characterized by dystrophy and/or dyschromia. Onychodystrophy is a widely used, yet rarely defined term. It refers to nail changes apart from changes of the color called nail dyschromia. From the patient's point of view partial or complete disruption of the various keratinous layers of the nail plate is most relevant. In every day life these changes are usually referred to as brittleness. For a better understanding of nail dystrophies the origin of the disorder should be first considered. The nail plate can be directly altered by exogenous factors. In this case the nail is primarily involved. But endogenous factors can also lead to a dystrophy of the nail plate. Then, changes in matrix, proximal nail fold, nail bed, hyponychium or underlying bony phalanx secondarily cause abnormal nails [7]. Unfortunately, there is only little known about the exact underlying pathophysiology leading to dys-

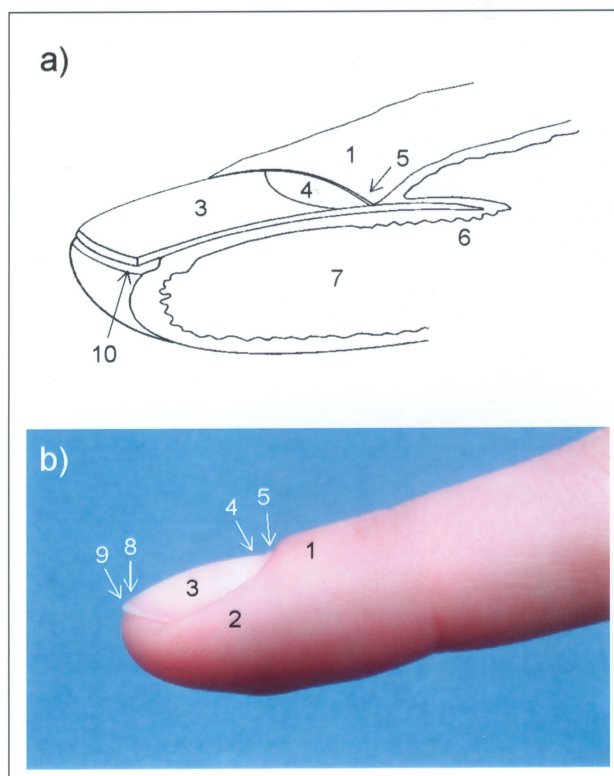


Figure 1:

a) Longitudinal section of a digit showing the nail unit (modified from [50]).

b) Corresponding image taken in a female young adult.

1) proximal nail fold, 2) lateral nail fold, 3) plate, 4) lunula, 5) cuticle, 6) matrix, 7) bed, 8) onychodermal band, 9) distal edge of plate, 10) hyponychium

Possible underlying diseases of onychodystrophy

- **congenital nail diseases**
- **onychomycosis**
- **other infections** of the nail apparatus (e.g. bacterial paronychia, herpes infections, scabies)
- **other skin diseases** involving the nail unit (e.g. psoriasis, eczema, lichen planus)
- **tumors** including benign (e.g. warts, digital mucoid cysts, subungual exostosis, glomus tumor) and malignant neoplasms (e.g. squamous cell carcinoma, basal cell carcinoma, malignant melanoma)
- **internal diseases** (e.g. chronic heart and lung diseases, hepatocirrhosis, nephritic syndrome)
- **drug reactions** (e.g. antimicrobial and antineoplastic chemotherapeutics)

Figure 2

trophies of the nails. Nevertheless, onychodystrophy is frequent.

Onychomycosis and nail psoriasis cause onychodystrophy most often

The most frequent nail disorders are onychomycosis and nail psoriasis, both well established diseases of the nail.

Onychomycosis represents 30-40% of the nail disorders [8]. The prevalence of nail psoriasis in patients with psoriasis of the skin amounted to about 80% of 1.728 psoriatic patients examined by de Jong et al. [9]. Clinically, onychomycosis and nail psoriasis have to be differentiated from many other types of diseases linked to onychodystrophy. To establish the underlying disease leading to nail dystrophy as a first step one should differentiate

between infectious and noninfectious disorders by obtaining nail material for microscopic examination and culture. If a fungus cannot be identified after repeating this examination several times a nonfungal disorder should be assumed. Moreover, the difficult path to the diagnosis requires a careful examination not only of the nails but also of the glabrous skin and mucous membranes of the patient. Sometimes nail biopsies are necessary. Occupation and cosmetic habits of the patient should be considered.

Systemic drug use can induce onychodystrophy

Beside onychomycosis and nail psoriasis systemic drugs often affect the nails. Pertinent changes range from mild pigmentation abnormalities to nail shedding and matrix scarring. Antimicrobial and antineoplastic chemotherapeutic agents including antimalarials as well as other drugs and poisons affect the nail in numerous ways [10]. E.g., dyschromia and dystrophy of the nail plate occurred after treatment with the antineoplastic drug docetaxel [11] and after treatment of rheumatoid arthritis with penicillamine [12]. Paronychia was described in association with the HIV protease inhibitor indinavir [13]. It is difficult to categorize the mechanism by which the nail change occurs. Most often toxicity to the matrix, to the nail bed or hyponychial region and to the periungual structures is assumed. Although the exact cause of the nail changes is unclear, ischemia, edema and disturbance of the cellular maturation is likely to play a major role [10]. The most common mechanism of action of antibiotics like the tetracycline family is relatively well understood: photosensitivity leads to onycholysis. But antibiotics also induce Beau's lines, nonspecific nail dystrophy and nail shedding [10]. Overall, as nail changes are most often not unique it may be difficult to incriminate a single drug.

Eczema of the fingertips and nail unit results in onychodystrophy

Just as endogenous factors like systemic drugs also exogenous factors can lead to a dystrophy of the nail plate. But in this case it is often laborious to find out the relevant external agents. Guin et al. [14] reported about three patients with prominent fingernail dystrophy and fingertip eczema. All patients were patch-test positive to cyanoacrylate used as an adhesive on artificial plastic fingernails. In addition, methyl methacrylate monomers and formaldehyde are known sensitizers and lead via allergic contact dermatitis to onycholysis through involvement of the subungual and periungual tissues [15], [16]. Marren et al. [17] reported about an occupational contact dermatitis which presented as nail dystrophy due to quaternium 15, which is commonly found in cosmetics and skin care products. In this case nail dystrophy preceded the hand eczema by several weeks. Consequently, patch testing should be performed to detect contact sensitivities to identify an underlying allergic contact

dermatitis in patients presenting with nail dystrophy. Moreover, it is worth noting that contact sensitivities involving the nails cause a distal dystrophy corresponding with the area of contact with the allergen. Thus, as a useful clinical sign, the nail matrix and proximal portions of the growing nail are unaffected. Just as allergic contact dermatitis also irritant dermatitis can cause onychodystrophy. Prolonged immersion in water plus repetitive mechanical trauma might be most often responsible for irritant dermatitis of the nails. Furthermore, nail dystrophy due to irritant dermatitis was observed after repetitive contact with sugar, enzyme detergents, sodium hypochlorite and hydrofluoric acid [16]. We think that isolated or repetitive mechanical trauma, dehydration of the nail and prolonged exposure to liquids, alkali and solvents are an underestimated cause of nail dystrophy. We propose the existence of a dermatitis primarily affecting the nail and suggest the term onychitis which should be further classified as irritant or allergic (Figure 3, Figure 4). To clarify the exact reason it is obvious that the patient should be carefully questioned about his or her occupation, cosmetic habits and previous therapy.

Aspects of the influence of onychodystrophy on quality of life

Diseases of the nail are underscored but it is likely that onychodystrophy affects quality of life including physical and social functioning and emotional health. Common complaints of patients with onychomycosis are nail trimming problems, difficulty to walk, discomfort in wearing shoes, pain, nail pressure and embarrassment [18], [19]. Extensive fingernail involvement and disability is noted because of the need for fingernails in picking up small objects like buttons and coins [19]. In order to measure the impact of onychomycosis on patient quality of life Turner and Testa [20] developed an onychomycosis disease-specific questionnaire that assessed symptom distress, functional impact and social stigma associated with the disease. Significant differences in physical functioning, emotional health and social functioning were found between clinically cured, improved or failed patients [20]. In light of its complications such as cellulitis, pain and extensive dermatophytic infections onychomycosis should be considered a medical condition that deserves rigorous clinical management [18]. Psoriasis of the nails also influences quality of life. About 52% of the patients who were interviewed by de Jong et al. [9] suffered from pain caused by their nail changes and a large subgroup of these patients was restricted in their daily activities, housekeeping and profession.

Measurement of nail growth and the corresponding influence of drugs

Clinicians used to observing the slow rate of clearance of diseased or damaged nails tend to see the nail apparatus as a static and inert tissue. However, to answer the

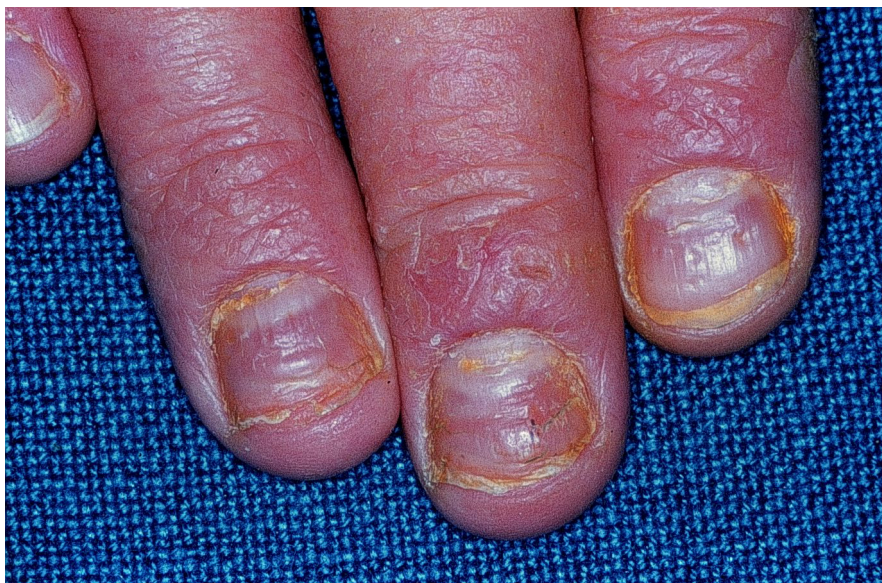

Figure 3: Formalin-induced contact dermatitis of the nails

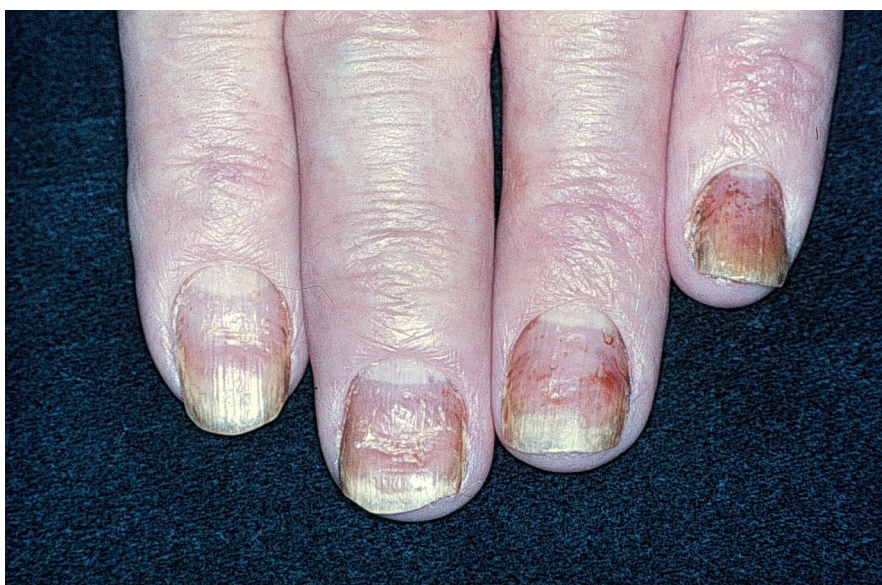

Figure 4: Dermatitis of the nails in a patient with atopy

question whether nails are alive or dead one should realize that the germinative layers of the nail matrix continue to divide, undertake DNA synthesis and differentiate to produce the nail plate throughout life. Thus with the criterium of growth nails fulfil a hallmark of life [21]. Nail growth has been studied by many authors employing several different methods; e.g., observation of the distal movement of a reference point on the nail plate [21], following up changes in the volume of nail indentations drilled with a dental burr until they grow out of the nail [22] and examination of the microrelief of the nail surface by computerized optical profilometry [23]. Nail growth can lead to elongation or thickening of the nail plate. Normal fingernail growth is assumed to vary from less than 1.8 and to more than 4.5 mm per month [24]. The middle finger shows the greatest rate, while thumb and little finger show the slowest rate of nail growth [25]. Several factors affect nail growth [21]. Faster growth is

observed during daytime, pregnancy, in summer, on right hand nails, due to minor trauma and in patients with psoriasis, pityriasis rubra pilaris and hyperthyroidism. Old age, cold environment, immobility, poor nutrition, hypothyroidism as well as some rare and unusual conditions such as the yellow nail syndrome lead to slower growth of the nails [21]. But whereas nails grow more slowly in older people they become thicker. Thus, the same unit mass of nail might be formed each day also in old people. Nail growth measurements in a patient with yellow nail syndrome revealed that longitudinal growth in the affected thumb nail was half that in the normal thumb nail. However, nail thickness in the yellow nail was double that in the normal nail [26]. Moffit and de Berker [26] suggest that the nail that grows half as fast grows twice as thick. Thus, rate of longitudinal growth does not necessarily reflect nail plate production. The authors speculate that in yellow nail syndrome the rate of nail production by the

matrix might be the same in affected nails and normal nails, but that some factor causes an altered orientation of nail growth in the abnormal nail [26]. It is commonly believed that yellow nail syndrome which is characterized by the classical triad of lymphedema, recurrent pleural effusion and yellow nails is due to an abnormality of the lymphatic vessels. D'Alessandro et al. [27] speculated that increased microvascular permeability due to capillary leakage and associated hypoalbuminaemia may contribute to the pathogenesis of this syndrome. Finally, they found a severe microangiopathy by nail fold capillaroscopy and photoplethysmography of both hands. Thus, in addition to lymphatic abnormality microangiopathy and increased microvascular filtration at pleura, intestine and limbs could play a role in this syndrome [27].

Increased longitudinal nail growth was reported for various drugs. De Doncker and Pierard [23] demonstrated a dose-dependent increase of the growth rate of infected nails for the triazole antifungal itraconazole. But, as fungal infections of the nail unit slow down nail growth, it is unclear whether itraconazole primarily accelerates the turnover rate of matrix cells [23].

An increase in longitudinal nail growth was also observed in psoriatics who were treated with retinoids, whereas treatment with etretinate had no effect on the daily growth rate of patients with other dermatoses which are known to have a good response to aromatic retinoids [28].

Treatment with topical Vitamin E led to clinical improvement of nail changes in yellow nail syndrome with a corresponding increase in nail growth rates [29]. Improvement of yellow nails was also found following treatment with oral vitamin E and more discernible subsequent to the introduction of itraconazole pulse therapy for secondary onychomycosis suggesting an effect of this treatment on ungual growth [30]. However, patients expect from their nail normal color and structure rather than increased growth [31]. Thus, patients would be rather interested in a nail plate normalizer than a nail growth enhancer as such. In particular for the huge variety of non-onychomycosis nail diseases there is a big demand for additional options of drug treatment.

Further approaches to objective measurement of treatment effects

Even if therapeutic effects can be evaluated by the patient and the physician it would be desirable to have further objective measuring systems. Potential objective parameters of healthy nails are thickness and volume of the nail and volume of the matrix as well. 20 MHz ultrasound offers an objective, but noninvasive, method to investigate these parameters showing characteristic quantitative changes in different skin diseases [32]. Using this technique Wollina et al. demonstrated that in patients with systemic lupus erythematosus nail thickness and matrix volume were increased, whereas patients with progressive systemic sclerosis showed a decrease in nail thickness and matrix volume. Unfortunately, in other diseases including psoriasis, eczema, onychomycosis and brittle

nails these measurements disclosed no confident differences to healthy controls [32]. Scanning electron microscopy is another interesting method for analyzing the structure of nails. Processing nail edge clippings thus the thickness of the nails can be measured, lamellar splitting and dorsal nail surface can be assessed in order to corroborate clinical results of therapeutic strategies [33]. Also, high-resolution magnetic resonance imaging (MRI) provides a new tool for the investigation of pathology of the nail apparatus and might be also useful in the diagnosis and clarification of the physiopathology of underlying diseases of onychodystrophy. While the diagnostic value of these methods seems obvious they seemingly have not yet been evaluated in drug trials.

Therapeutic aspects: systemic therapy of onychodystrophy

Various topical and systemic therapies have been performed to investigate their potential beneficial role in disorders of the nail. The modern and effective antifungal agents itraconazole, fluconazole and terbinafine are of special interest as onychomycoses represent the most frequently seen nail diseases. Evans and Sigurgeirsson [34] demonstrated a clinical cure rate of 60%, a mycological cure rate of about 80% and a complete cure rate (clinical and mycologic cure) of 55% at week 72 in patients with toenail onychomycosis treated with terbinafine 250mg/d for 16 weeks. Also a long term benefit was observed by Bräutigam et al. [35] who followed up patients three years after a successful treatment of toenail mycosis with terbinafine and itraconazole. Thus, at least in part onychodystrophy is curable if antagonizing the pathogenetically relevant reason. However, about 20-30% of the patients must expect treatment failure or relapse following treatment of onychomycosis [36]. A possible advance towards higher cure rates might be the combination of drugs to produce synergistic activity [36], [37]. Predisposing factors for onychomycosis [38], [39], [40] are arterial and venous circulation disorders, neuropathy, diabetes mellitus, trauma and an osteoarticular pathology like defective position of the feet. However, these diseases can independently lead to onychodystrophy, which often cannot be distinguished from subungual onychomycosis and perhaps existed before mycological infection occurred. This must be also considered if nails remain dystrophic after mycologically speaking successful antimycotic therapy.

Amongst the general public there is a widespread belief that supplementation of calcium improves quality of fingernails and toenails. However, a randomized, placebo-controlled trial provided no support for the idea that dietary calcium intake alters nail quality in healthy postmenopausal women [41].

A favourable response to oral application of biotin for defect hooves of horses or claws of pigs has been documented in veterinary medicine. For some human patients with brittle fingernails and onychoschizia an effective therapy with biotin was described resulting in increased

thickness of the nail with firmer and harder nails and reduced splitting, yet not in double blind controlled trials [33], [42], [43]. Generalized hyperpigmentation of skin and nails in a patient with vitamin B12 deficiency due to pernicious anemia returned to normal after treatment with intramuscular cyanocobalamin [44].

Therapeutic aspects: topical therapy of onychodystrophy

Topical and intralesional glucocorticoid applied to the proximal nail fold for therapy of nail dystrophy associated with various underlying skin disorders such as atopic dermatitis, psoriasis and lichen planus are regarded as safe and acceptable treatment options [45], [46], [47]. In the treatment of nail psoriasis topical calcipotriol shall represent an effective and safe alternative [46]. While topical and in particular intralesional treatment is common, for the patient this therapy is time-consuming and disappointing if there is no marked improvement. It is assumed that topical glucocorticoid therapy under plastic film occlusion increases efficacy. It has been shown that in dystrophic psoriatic fingernails the nail penetration enhancer Belanyx® (urea, propylene glycol) improves the nail pitting area, number of nail pits, subungual keratosis, onycholysis and oil spots [48]. It could be also demonstrated that addition of 1% fluorouracil to Belanyx® does not increase the efficacy of the active agent in psoriatic nail dystrophy [48].

Conclusions

In conclusion, onychodystrophy by principle is open to effective treatment. This in particular applies to onychodystrophy caused by onychomycosis. As noninfectious onychodystrophy seems to be linked most often to exogenous damaging factors it looks rewarding to search for them vigorously to make consequent avoidance feasible. Nevertheless, there clearly still is medical need for additional options of drug treatment. Current approaches too often still disappoint patients. Moreover, the wanted effects attributed to them as a rule are not well backed by adequate clinical trials.

The nail plate is a difficult barrier for drugs to penetrate. Therefore, the bioavailability of drugs after topical or oral administration in the nail plate represents a pivotal problem of nail therapy. To be effective the drug must successfully penetrate the keratinized tissue. For the nails, especially the toenails, penetration after oral administration is impeded by their slow growth and by specific conditions that retard the rate of nail growth, such as advanced age and yellow nail syndrome. Adequately devised nail patches might prove to be at least one useful solution to the problem.

We suppose that irritant dermatitis of the nails is an underestimated reason for onychodystrophy. Barrier creams were shown to be efficient improving the clinical skin status and stratum corneum hydration in the treatment

of occupational irritant contact dermatitis of glabrous skin [49]. If applicable the development of a protection lacquer with a barrier function for the nail plate might help preventing irritant onychitis in the future.

References

- González-Serva A. Structure and function. In: Scher RK, Daniel CR, editors. *Nails: therapy, diagnosis, surgery*. Philadelphia, London: Saunders, 1990:11-30.
- Scher RK. Nail surgery. *Clin Dermatol* 1987;5:135-142.
- Runne U, Orfanos CE. The human nail: structure, growth and pathological changes. *Curr Probl Dermatol* 1981;9:102-149.
- Dawber RPR, de Berker DAR, Baran R. Science of the nail apparatus. In: Baran R, Dawber RPR, de Berker DAR, Haneke E, Tosti A, editors. *Baran and Dawber's diseases of the nails and their management*. 3 ed. Oxford, London: Blackwell Science, 2001:1-47.
- Scher RK, Daniel CR. *Nails: therapy, diagnosis, surgery*. Philadelphia, London: Saunders, 1990.
- Tosti A, Piraccini BM. Treatment of common nail disorders. *Dermatol Clin* 2000;18:339-348.
- Baran R, Kechijian P. Understanding nail disorders. *Eur J Dermatol* 2001;11:159-162.
- Haneke E. Fungal infections of the nail. *Semin Dermatol* 1991;10:41-53.
- de Jong EM, Seegers BA, Gulinck MK, Boezeman JB, van de Kerkhof PC. Psoriasis of the nails associated with disability in a large number of patients: results of a recent interview with 1,728 patients. *Dermatology* 1996;193:300-303.
- Daniel CR, Scher RK. Nail changes secondary to systemic drugs or ingestants. *J Am Acad Dermatol* 1984;10:250-258.
- Correia O, Azevedo C, Pinto Ferreira E, Braga Cruz F, Polonia J. Nail changes secondary to docetaxel (Taxotere). *Dermatology* 1999;198:288-290.
- Bjellerup M. Nail-changes induced by penicillamine. *Acta Derm Venereol* 1989;69:339-341.
- Colson AE, Sax PE, Keller MJ, Turk BK, Pettus PT, Platt R, et al. Paronychia in association with indinavir treatment. *Clin Infect Dis* 2001;32:140-143.
- Guin JD, Baas K, Nelson-Adesokan P. Contact sensitization to cyanoacrylate adhesive as a cause of severe onychodystrophy. *Int J Dermatol* 1998;37:31-36.
- Kassis V, Vedel P, Darre E. Contact dermatitis to methyl methacrylate. *Contact Dermatitis* 1984;11:26-28.
- Kern DG. Occupational Disease. In: Scher RK, Daniel CR, editors. *Nails: therapy, diagnosis, surgery*. Philadelphia, London: Saunders, 1990:224-243.
- Marren P, de Berker D, Dawber RP, Powell S. Occupational contact dermatitis due to quaternium 15 presenting as nail dystrophy. *Contact Dermatitis* 1991;25:253-255.
- Elewski BE. Onychomycosis. Treatment, quality of life, and economic issues. *Am J Clin Dermatol* 2000;1:19-26.
- Millikan LE, Powell DW, Drake LA. Quality of life for patients with onychomycosis. *Int J Dermatol* 1999;38 Suppl 2:13-16.
- Turner RR, Testa MA. Measuring the impact of onychomycosis on patient quality of life. *Qual Life Res* 2000;9:39-53.
- Dawber R, Baran R. Nail growth. *Cutis* 1987;39:99-103.

22. Heikkilä H, Stubb S, Kiistala U. Nail growth measurement employing nail indentation—an experimental follow-up study of nail growth in situ. *Clin Exp Dermatol* 1996;21:96-99.
23. Doncker PD, Pierard GE. Acquired nail beading in patients receiving itraconazole—an indicator of faster nail growth? A study using optical profilometry. *Clin Exp Dermatol* 1994;19:404-406.
24. Hamilton JB, Terada H, Mestler GE. Studies of growth throughout the lifespan in Japanese: Growth and size of nails and their relationship to age, sex, hereditary, and other factors. *J Gerontol* 1955;10:401.
25. Le Gros CW, Buxton LDH. Studies in nail growth. *Br J Dermatol* 1938;50:221-235.
26. Moffitt DL, de Berker DA. Yellow nail syndrome: the nail that grows half as fast grows twice as thick. *Clin Exp Dermatol* 2000;25:21-23.
27. D'Alessandro A, Muzi G, Monaco A, Filiberto S, Barboni A, Abbritti G. Yellow nail syndrome: does protein leakage play a role? *Eur Respir J* 2001;17:149-152.
28. Galosi A, Plewig G, Braun-Falco O. The effect of aromatic retinoid Ro 10-9359 (etretinate) on fingernail growth. *Arch Dermatol Res* 1985;277:138-140.
29. Williams HC, Buffham R, du Vivier A. Successful use of topical vitamin E solution in the treatment of nail changes in yellow nail syndrome. *Arch Dermatol* 1991;127:1023-1028.
30. Luyten C, Andre J, Walraevens C, De Doncker P. Yellow nail syndrome and onychomycosis. Experience with itraconazole pulse therapy combined with vitamin E. *Dermatology* 1996;192:406-408.
31. Draelos ZD. Nail cosmetic issues. *Dermatol Clin* 2000;18:675-683.
32. Wollina U, Berger M, Karte K. Calculation of nail plate and nail matrix parameters by 20 MHz ultrasound in healthy volunteers and patients with skin disease. *Skin Res Technol* 2001;7:60-64.
33. Colombo VE, Gerber F, Bronhofer M, Floersheim GL. Treatment of brittle fingernails and onychoschizia with biotin: scanning electron microscopy. *J Am Acad Dermatol* 1990;23:1127-1132.
34. Evans EG, Sigurgeirsson B. Double blind, randomised study of continuous terbinafine compared with intermittent itraconazole in treatment of toenail onychomycosis. The LION Study Group. *Brit Med J* 1999;318:1031-1035.
35. Bräutigam M, Weidinger G, Nolting S. Successful treatment of toenail mycosis with terbinafine and itraconazole gives long term benefits [letter]. *Brit Med J* 1998;317:1084.
36. Evans EG. The rationale for combination therapy. *Br J Dermatol* 2001;145 Suppl 60:9-13.
37. Gupta AK, Baran R. Ciclopirox nail lacquer solution 8% in the 21st century. *J Am Acad Dermatol* 2000;43:S96-102.
38. Haneke E, Roseeuw D. The scope of onychomycosis: epidemiology and clinical features. *Int J Dermatol* 1999;38 Suppl 2:7-12.
39. Abeck D, Haneke E, Nolting S, Reinelt D, Seebacher C. Onychomykose. *Dt Ärztebl* 2000;97:A1984-1986.
40. Abeck D, Gruseck E, Korting HC, Ring J. Onychomykose: Epidemiologie, Pathogenese, Klinik, Mikrobiologie und Therapie. *Dt Ärztebl* 1996;93:A2027-2032.
41. Reid IR. Calcium supplements and nail quality. *N Engl J Med* 2000;343:1817.
42. Hochman LG, Scher RK, Meyerson MS. Brittle nails: response to daily biotin supplementation. *Cutis* 1993;51:303-305.
43. Floersheim GL. Behandlung brüchiger Fingernägel mit Biotin. *Z Hautkr* 1989;64:41-48.
44. Noppakun N, Swasdikul D. Reversible hyperpigmentation of skin and nails with white hair due to vitamin B12 deficiency. *Arch Dermatol* 1986;122:896-899.
45. Khoo BP, Giam YC. A pilot study on the role of intralesional triamcinolone acetonide in the treatment of pitted nails in children. *Singapore Med J* 2000;41:66-68.
46. Tosti A, Piraccini BM, Cameli N, Kokely F, Plozzer C, Cannata GE, et al. Calcipotriol ointment in nail psoriasis: a controlled double-blind comparison with betamethasone dipropionate and salicylic acid. *Br J Dermatol* 1998;139:655-659.
47. Piraccini BM, Tosti A, Iorizzo M, Misciali C. Pustular psoriasis of the nails: treatment and long-term follow-up of 46 patients. *Br J Dermatol* 2001;144:1000-1005.
48. de Jong EM, Menke HE, van Praag MC, van De Kerkhof PC. Dystrophic psoriatic fingernails treated with 1% 5-fluorouracil in a nail penetration-enhancing vehicle: a double-blind study. *Dermatology* 1999;199:313-318.
49. Berndt U, Wigger-Alberti W, Gabard B, Elsner P. Efficacy of a barrier cream and its vehicle as protective measures against occupational irritant contact dermatitis. *Contact Dermatitis* 2000;42:77-80.
50. Haneke E. Erkrankungen der Nägel. In: Plewig G, Korting HC, eds. *Fortschritte der praktischen Dermatologie und Venerologie* 1994 (14). Berlin: Springer, 1995: 204-210.

Corresponding author:

Prof. Dr. Hans Christian Korting
Klinik und Poliklinik für Dermatologie und Allergologie,
Ludwig-Maximilians-Universität München, Frauenlobstr.
9-11, 80337 München, Germany, Tel. +49-89-5160-
6203, Fax +49-89-5160-6204
H.C.Korting@lrz.uni-muenchen.de

Please cite as

Oppel T, Korting HC. Onychodystrophy and its management. *Ger Med Sci.* 2003;1:Doc02.

This article is freely available from

<http://www.egms.de/en/gms/2003-1/000002.shtml>

Received: 2003-05-02

Published: 2003-07-01

Copyright

©2003 Oppel et al. This is an Open Access article distributed under the terms of the Creative Commons Attribution License (<http://creativecommons.org/licenses/by-nc-nd/3.0/deed.en>). You are free to Share — to copy, distribute and transmit the work, provided the original author and source are credited.