

## Appendix 8: Individual Patient Report 8: patient 8: male, 34 years old

Small ulcer on medial side of left lower leg, approximately 15 cm cranial to ankle. The patient has had present ulcer for approximately 2 months. The patient has varicose veins on both legs and has had a previous open ulcer on the right leg, which took a long time to heal. The patient has not been previously operated for varicose veins. The patient had had thrombophlebitis on the right leg in August 2002. The patient is not a smoker. Presumably suboptimal compression therapy.

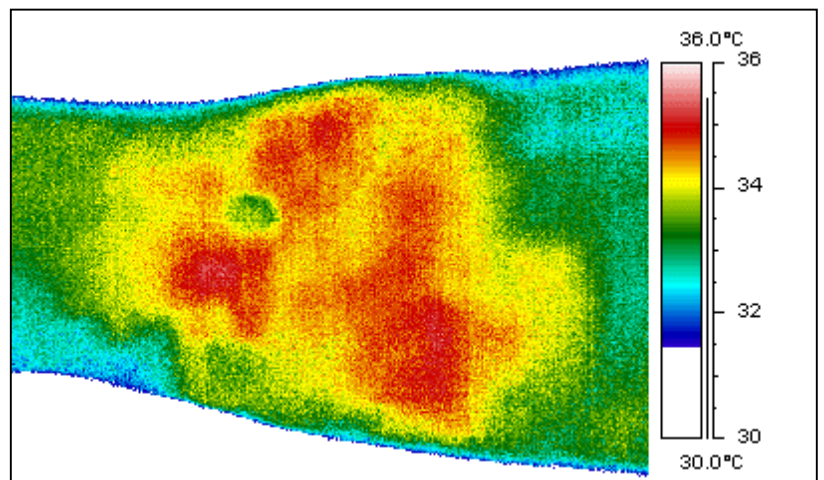
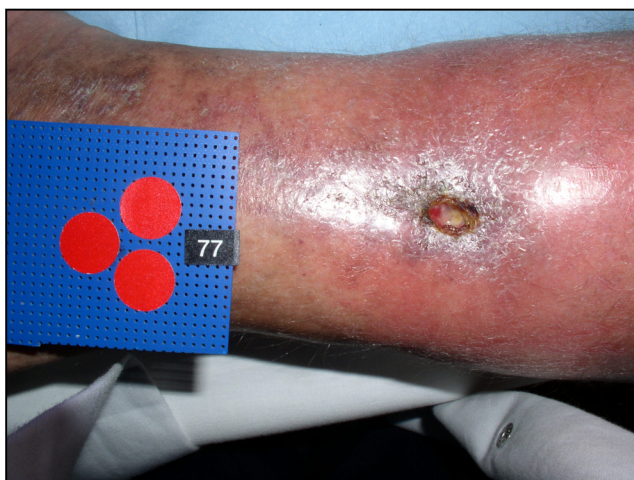*Peripheral blood pressure measurements:* slightly reduced bilateral ankle pressures and normal toe pressures.

*Duplex (ultrasound) scanning:* normal femoral and popliteal veins. Insufficiency of great and small saphenous veins and insufficient perforating vein on medial side of left lower leg.

A new bacterial infection was identified after treatment 8. The patient was put on penicillin treatment. Also two new small ulcers developed beside the main ulcer. The patient took a 10 day holiday between treatment 21 and 22. After the final wIRA treatment the ulcers were healed and the patient was referred for operation. Follow-up January 2006: the patient is symptom-free.

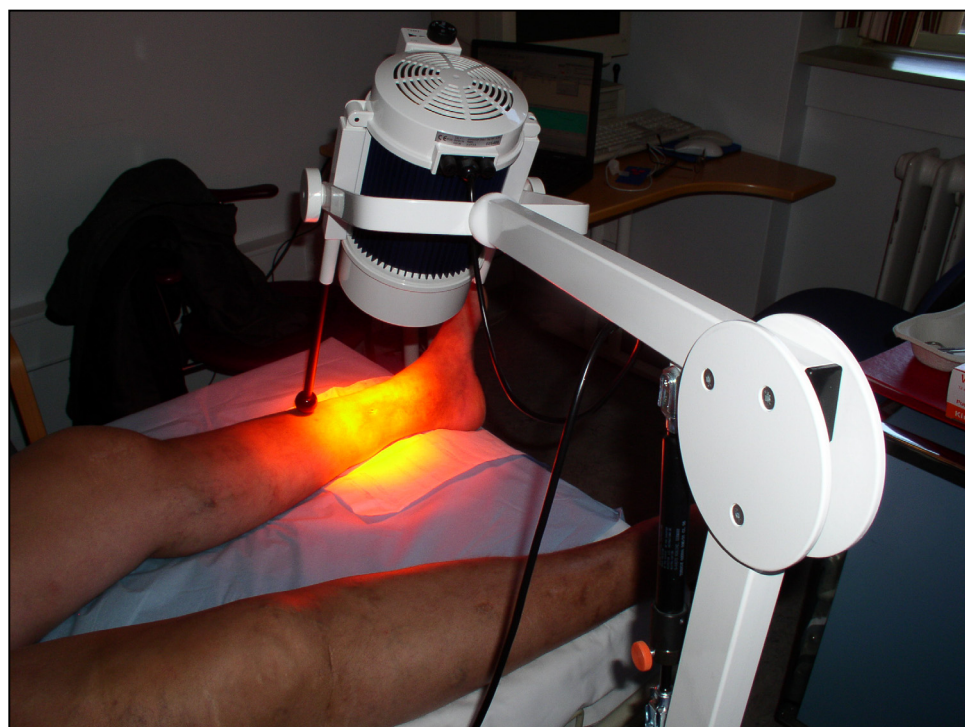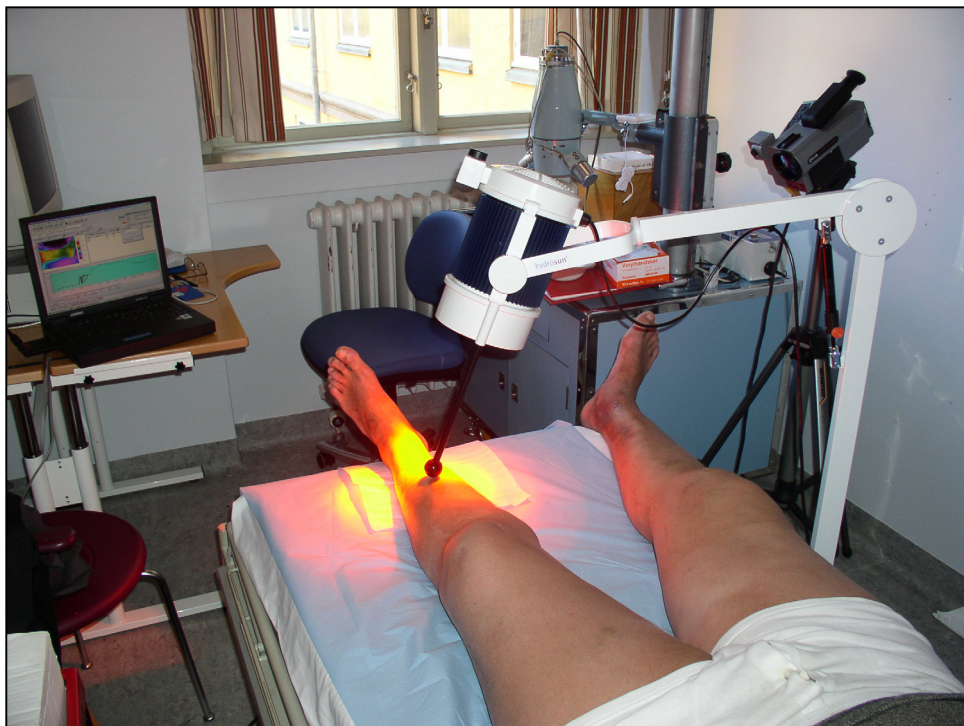This ulcer is classified as a venous ulcer (v) (chronic venous insufficiency stage 3 according to Widmer, which means chronic venous insufficiency with ulcer) without concomitant problems in Table 1 in the results section.

Total number of treatments:	27
First treatment:	2003-02-12
Last treatment:	2003-04-04
Total Treatment time:	48 days



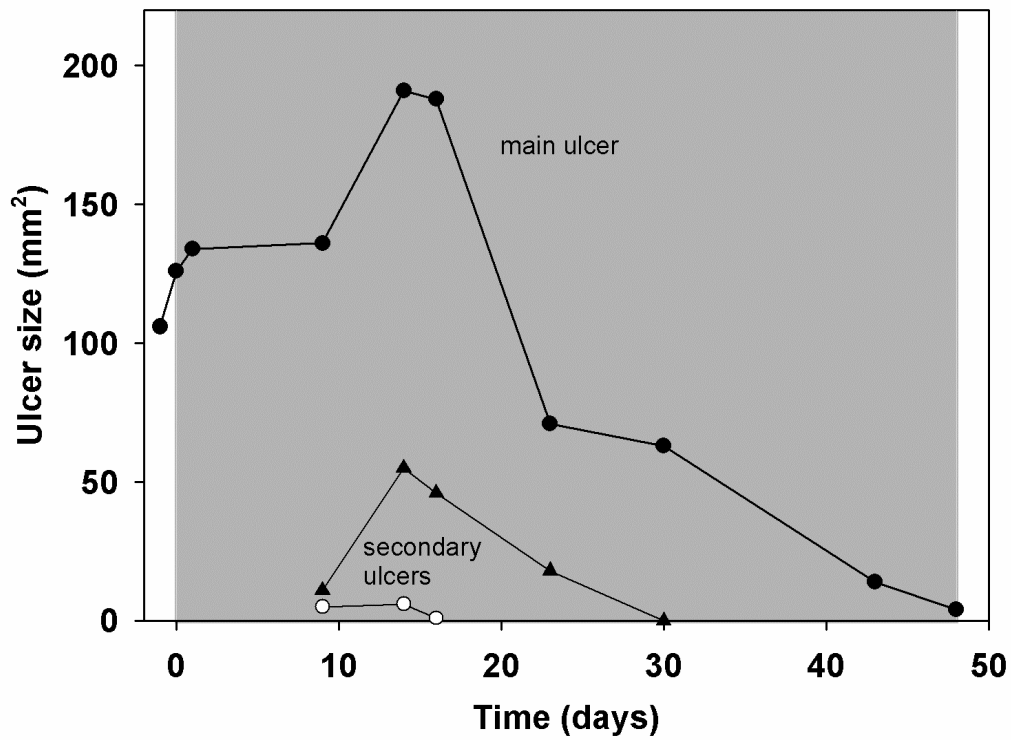
2003-02-11: first visit (1 day prior to first treatment) (infrared image on right)

Set-up for wIRA treatment. Note infrared camera in the background.

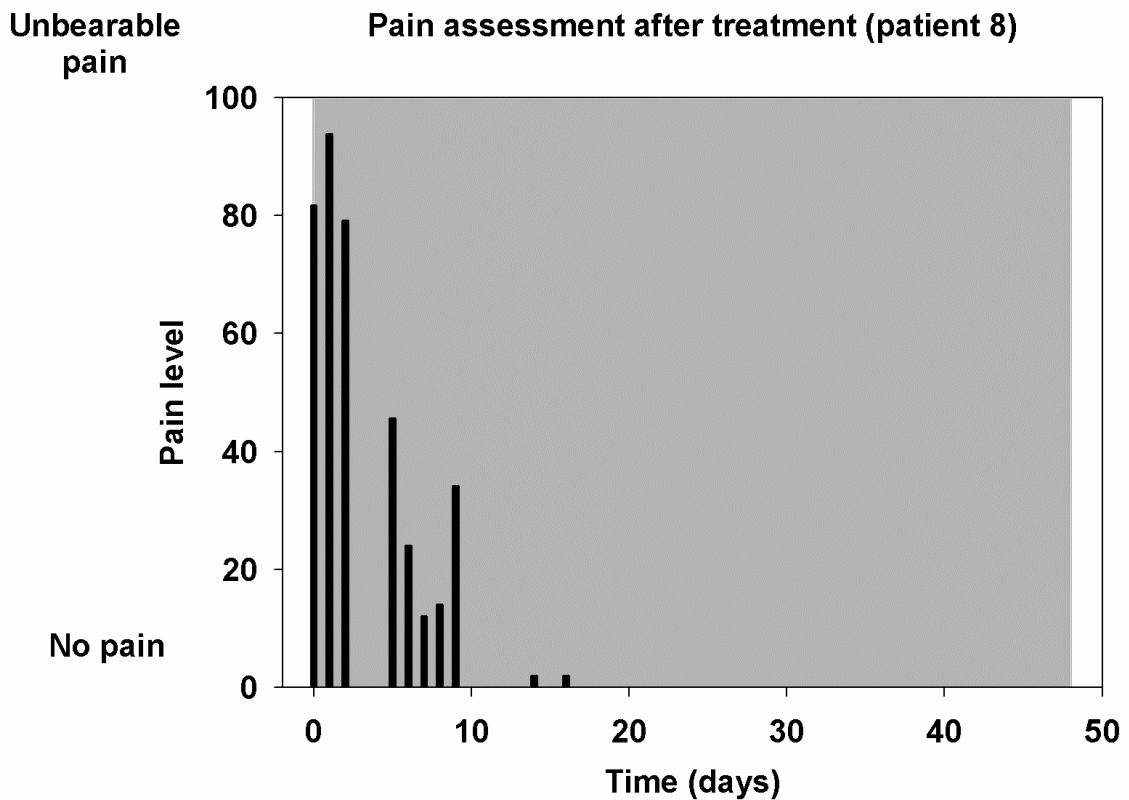
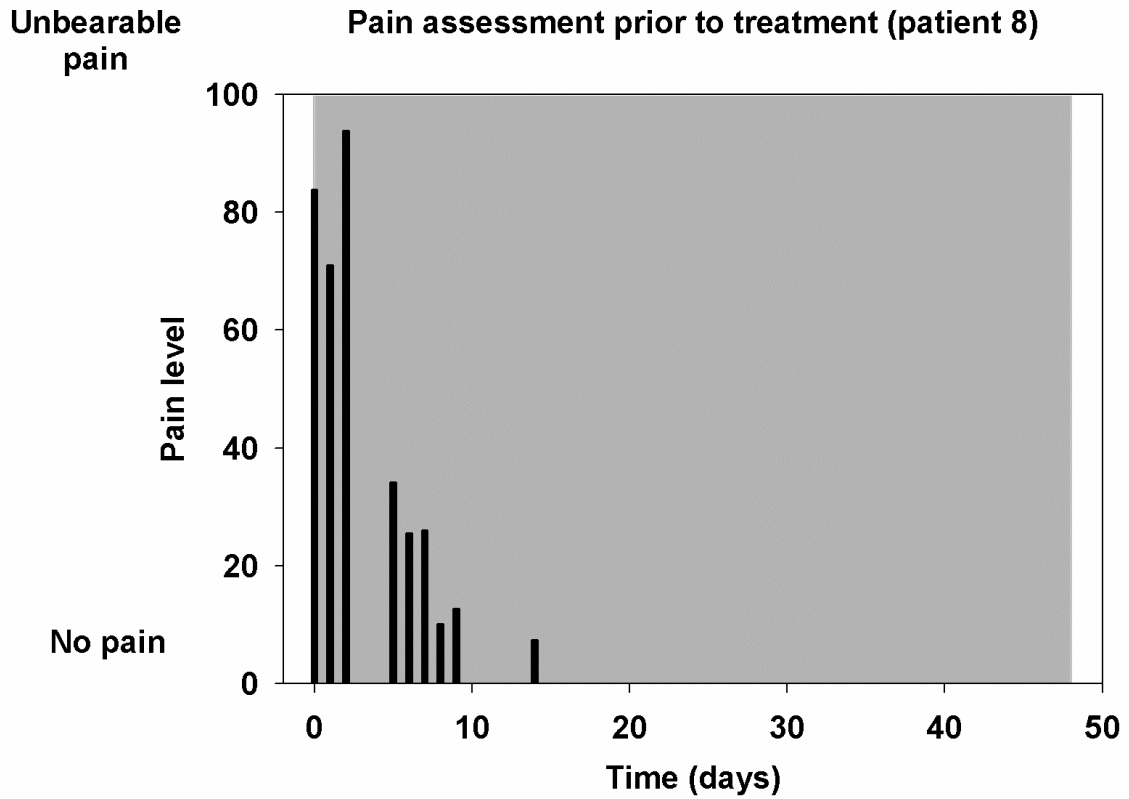


**Note:** In all following figures showing results related to time, the grey shaded area represents the entire wIRA treatment period for this patient (i.e., the total time period between the first and the last treatment).

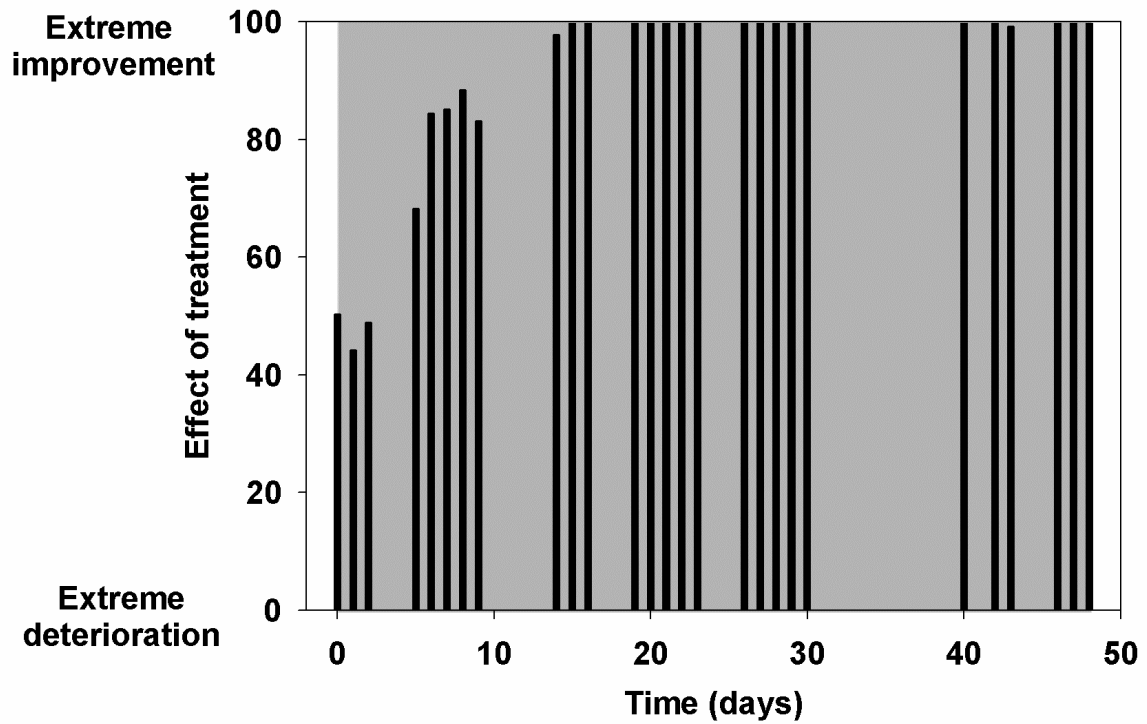
**Ulcer size (patient 8)**



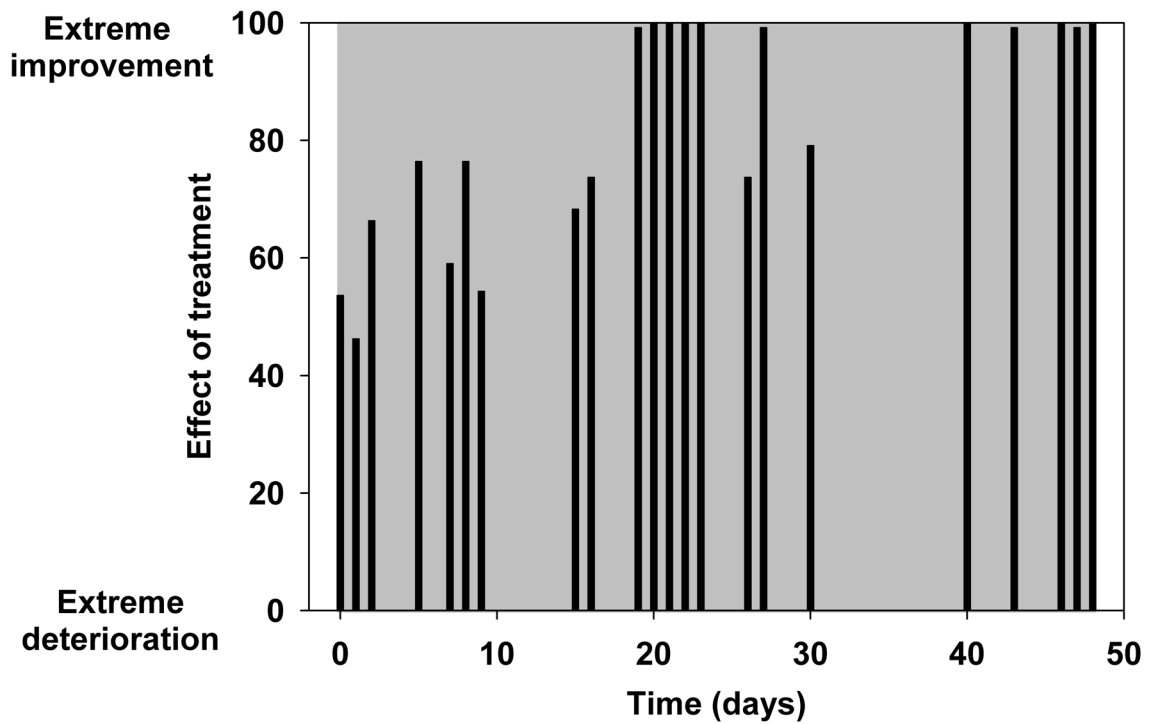




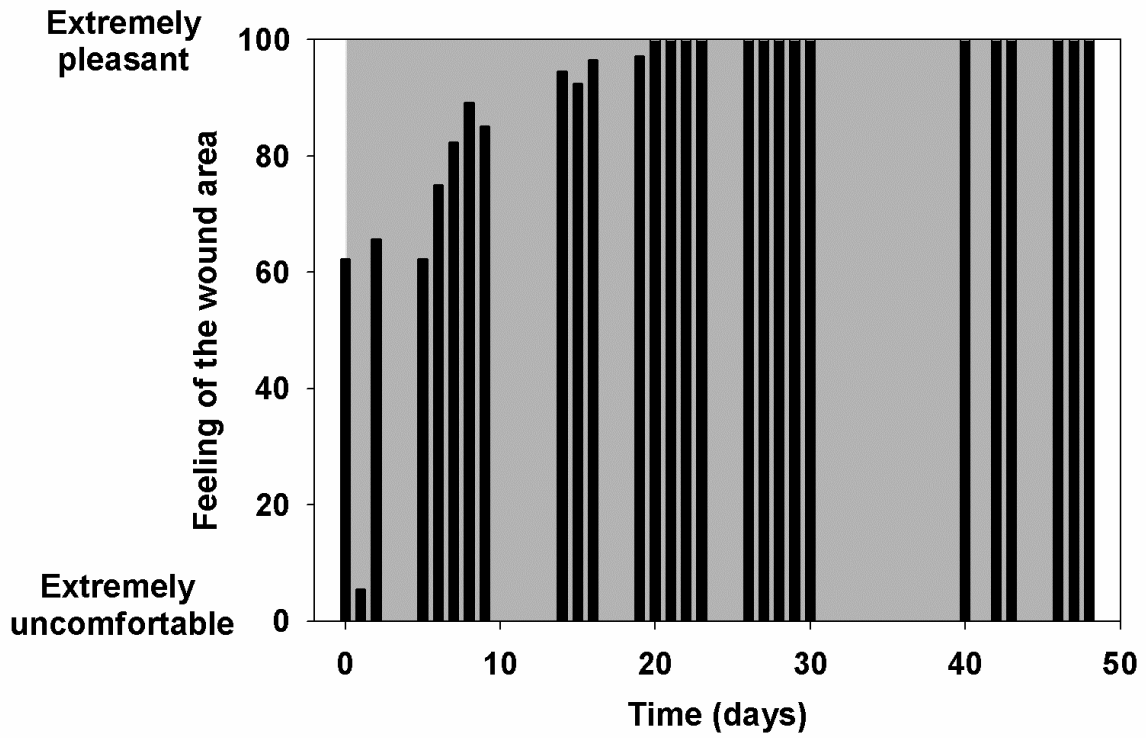
**Effect of treatment (patient 8's assessment)**



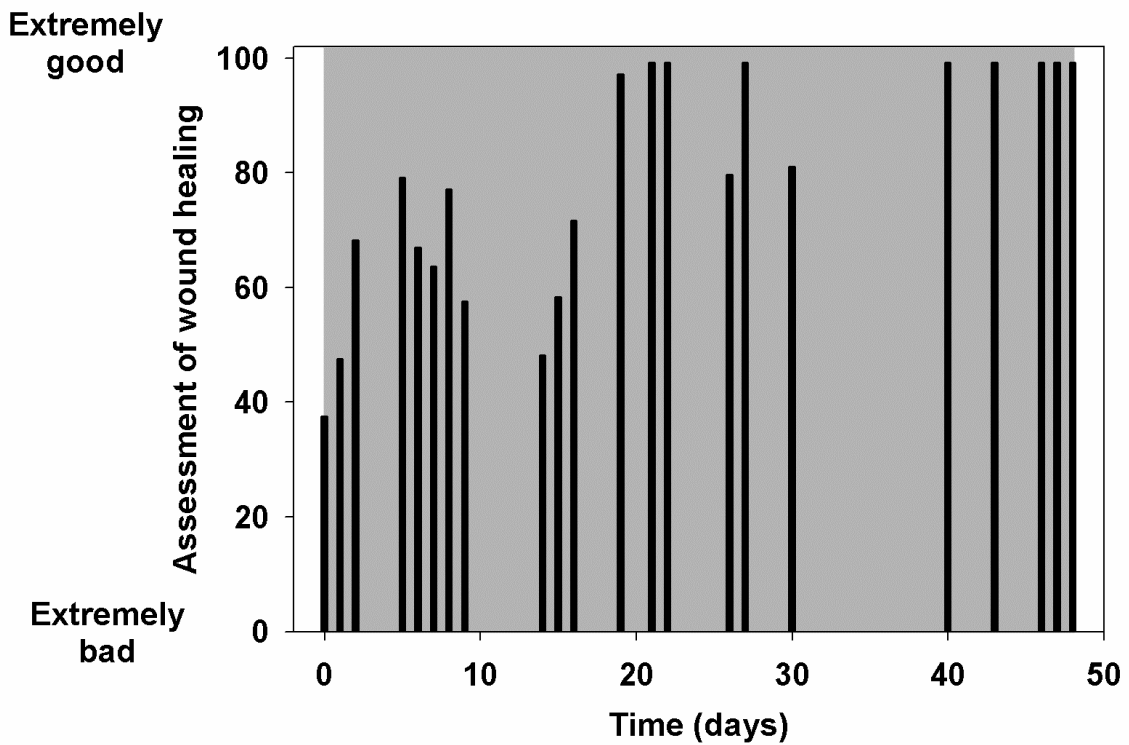
**Effect of treatment (investigator's assessment patient 8)**



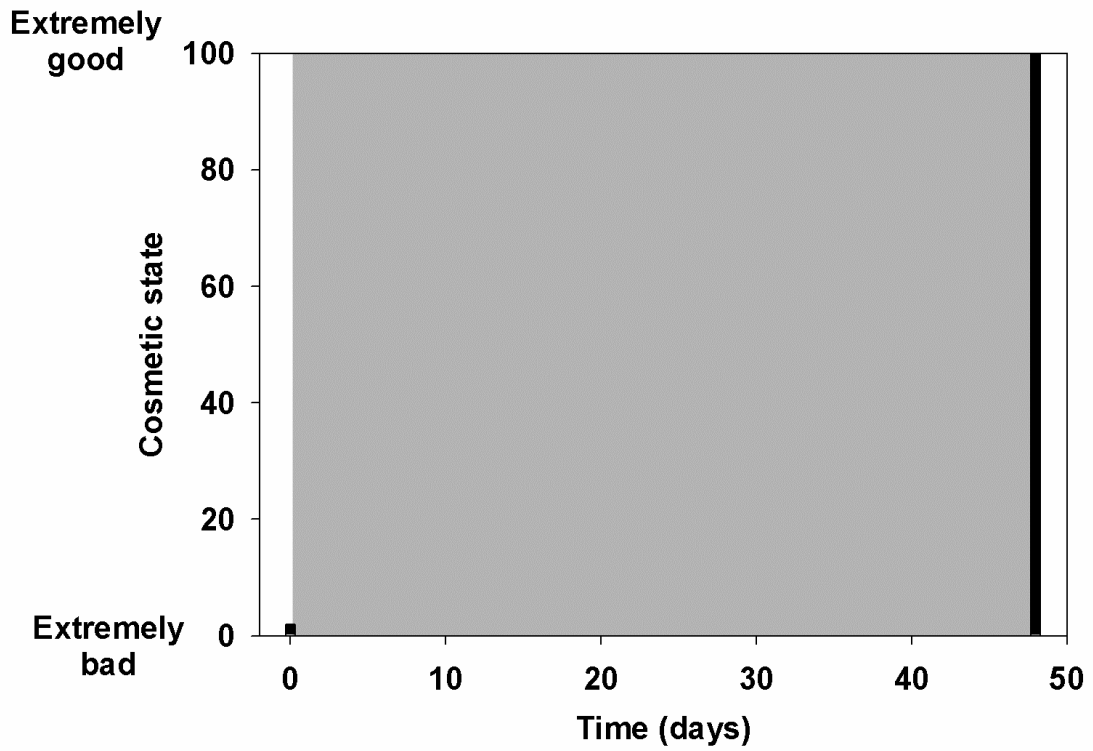
**Feeling of the wound area (patient 8's assessment)**



**Wound healing (investigator's assessment patient 8)**



### Cosmetic state (patient 8's assessment)



### Cosmetic state (investigator's assessment patient 8)

