

## Appendix 6: Individual Patient Report 6: patient 6: female, 56 years old

Chronic leg ulcer over lateral left malleolar region. Marked inflammation on left leg (see infrared image). The patient has had this ulcer for 4 weeks. The patient has had two previous ulcers. The wound is deep and painful to mechanical stimuli. The first treatment was short (15 minutes) rather than the standard 30 minutes. The patient had a second small wound approximately 2 cm rostral to the main ulcer. The patient is taking large amounts of pain killers (panodil) – up to 10 per day. Presumably suboptimal compression therapy.

During some of the first treatments the patient had to use lidocain gel in the ulcer to lessen the pain. Otherwise we could not treat the patient. Note: this could affect the evaluations.

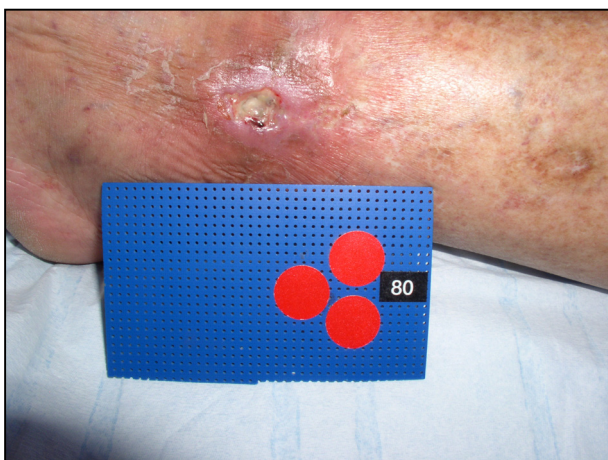
*Result of Duplex scanning:* insufficiency of great saphenous vein. Insufficient perforating vein cranial to the ulcer. Normal peripheral blood pressures.

*Conclusion:* superficial venous insufficiency.

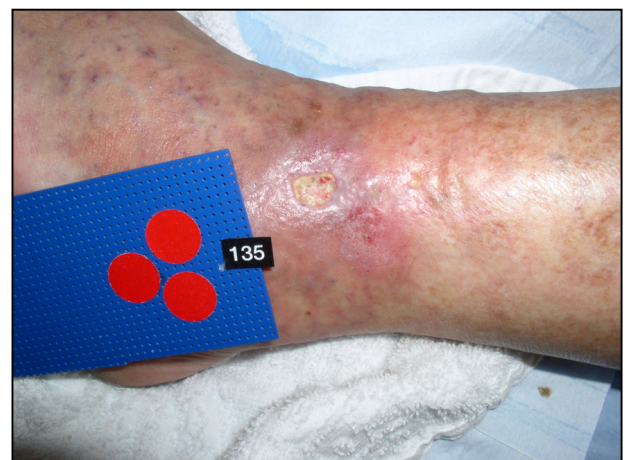Due to termination of the project the wIRA treatment was terminated before the ulcer was healed. The pain problem returned and the patient was admitted to hospital in summer of 2003. The patient did not stop smoking. During the hospital stay the patient received morphine (3 mg 3 times a day). On October 31, 2003 the patient underwent surgical intervention with resection of stella venosa and great saphenous vein and closure of the perforating vein. Following this procedure the ulcer healed and the patient was pain free.

This ulcer is classified as a venous ulcer (v) (chronic venous insufficiency stage 3 according to Widmer, which means chronic venous insufficiency with ulcer) with concomitant problem (smoking) in Table 1 in the results section.

|                             |   |
|-----------------------------|---|
| Total number of treatments: | 29  |
| First treatment:            | 2003-02-17                                |
| Last treatment:             | 2003-04-04                                |
| Total treatment period:     | 44 days                                   |
| Smoker:                     | yes (approximately 15 cigarettes per day) |



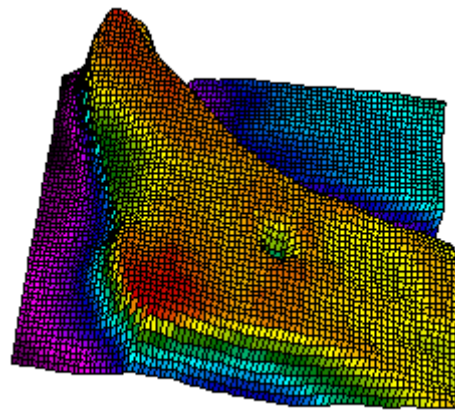
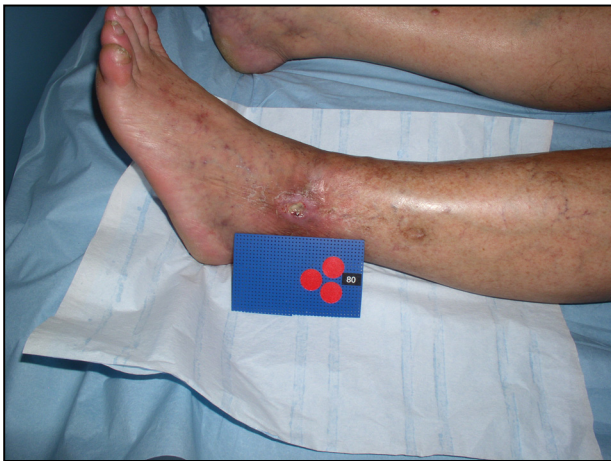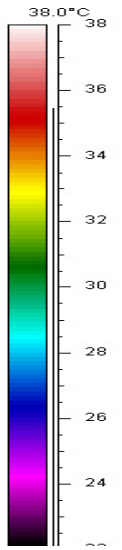
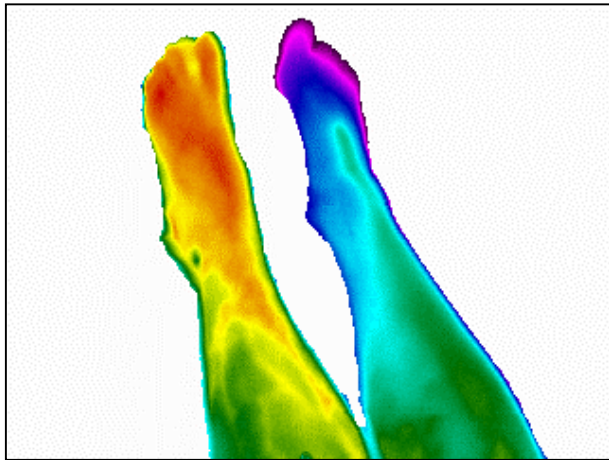
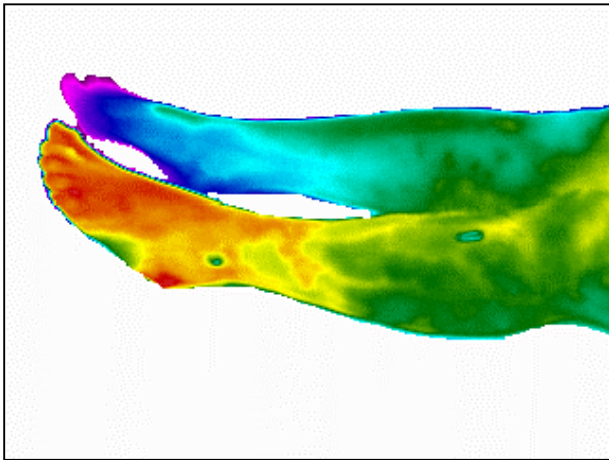
2003-02-12



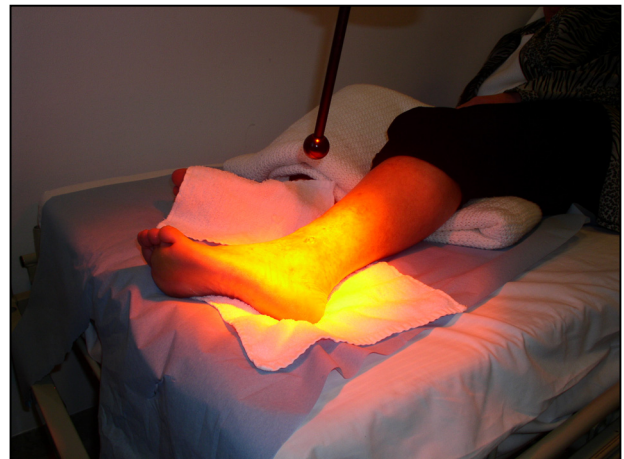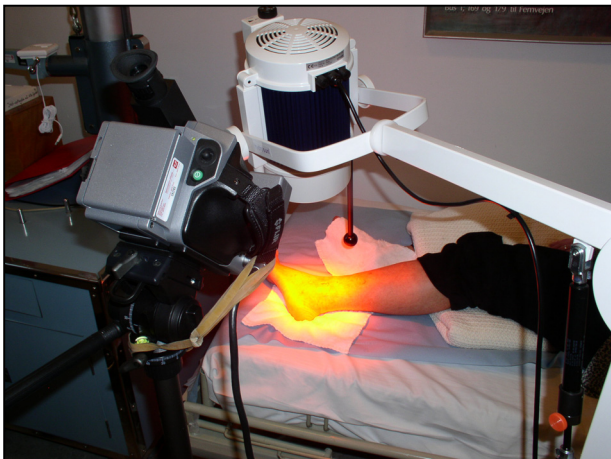
2003-03-27

2003-02-12: first visit (5 days prior to the first treatment)

Infrared images of the ulcer

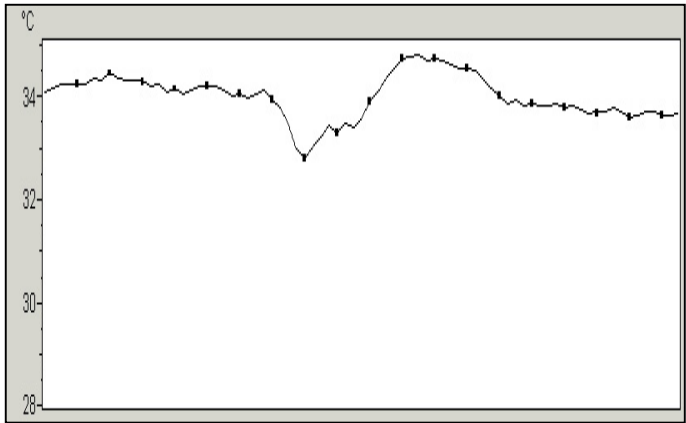
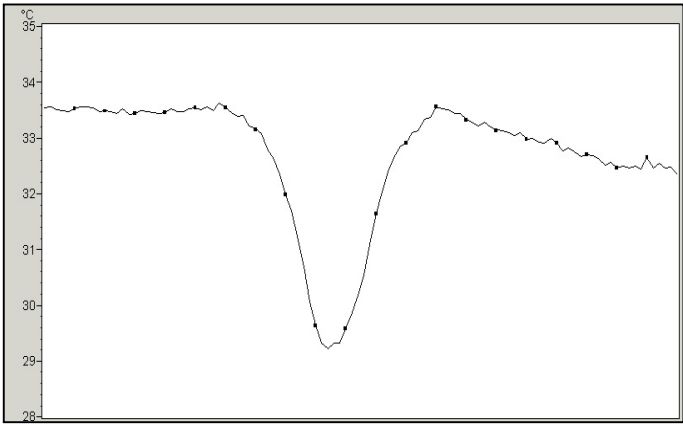
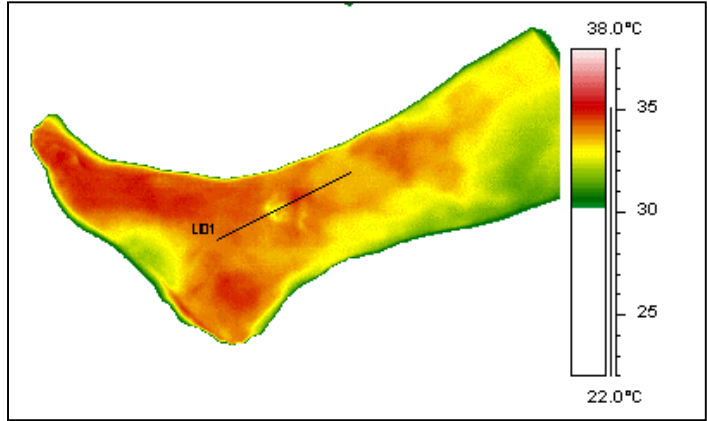
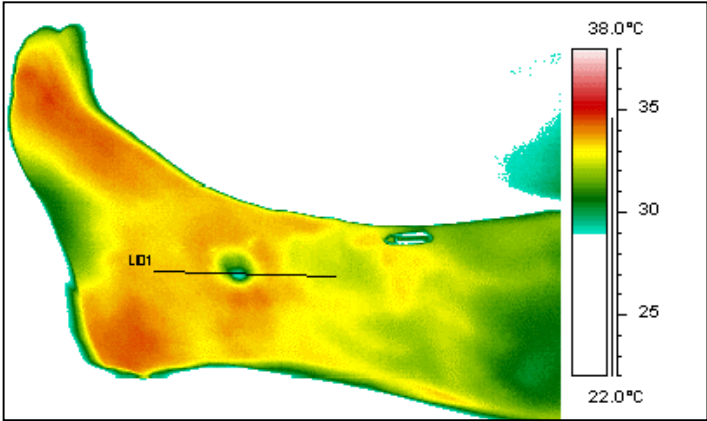


Treatment set-up with wIRA radiator and infrared camera



2003-02-12

2003-03-21



| Label  | Min  | Max  | Avg  |
|--------|------|------|------|
| LI01 - | 29.2 | 33.6 | 32.7 |

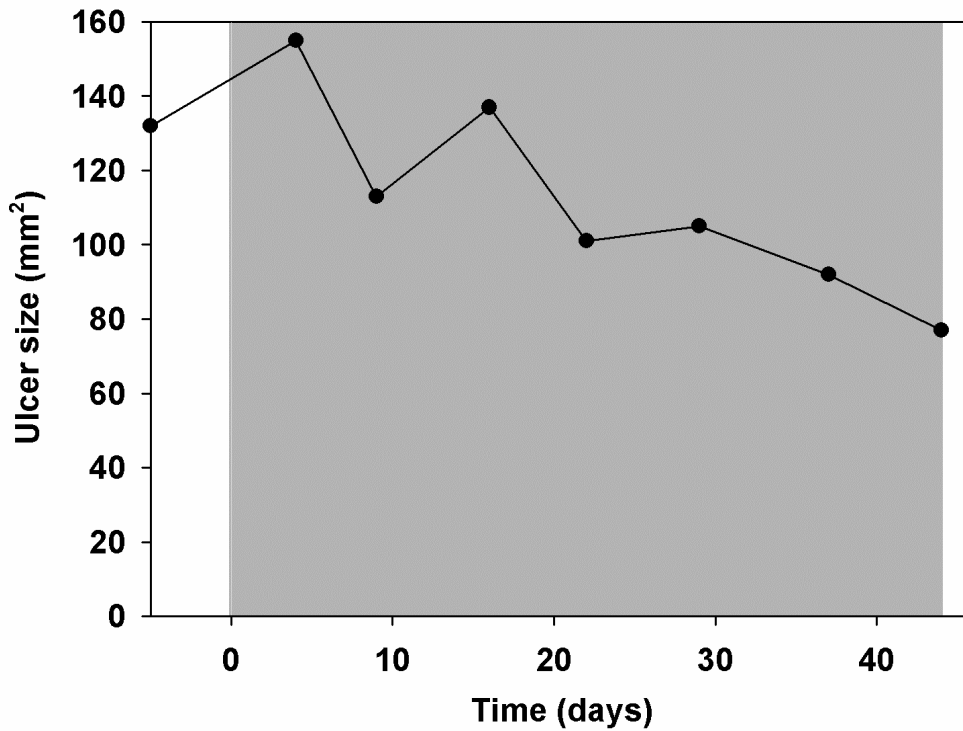
| Label  | Min  | Max  | Avg  |
|--------|------|------|------|
| LI01 - | 32.8 | 34.8 | 34.0 |

Temperature profiles through the infrared images

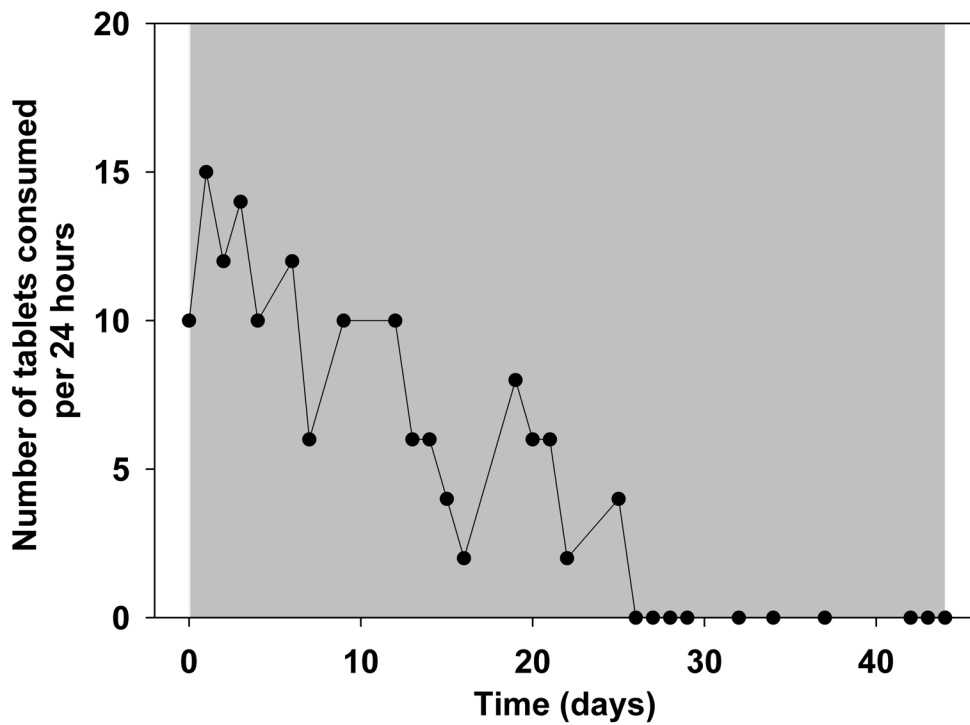
Note the remarkably hypothermic situation of the ulcer base at the beginning! The temperature of the ulcer base is approximately 4°C less than the temperature of the surrounding skin (without markedly hyperthermic ulcer rim) and the ulcer base is not only relatively but as well absolutely hypothermic (29.2°C)!

**Note:** In all following figures showing results related to time, the grey shaded area represents the entire wIRA treatment period for this patient (i.e., the total time period between the first and the last treatment).

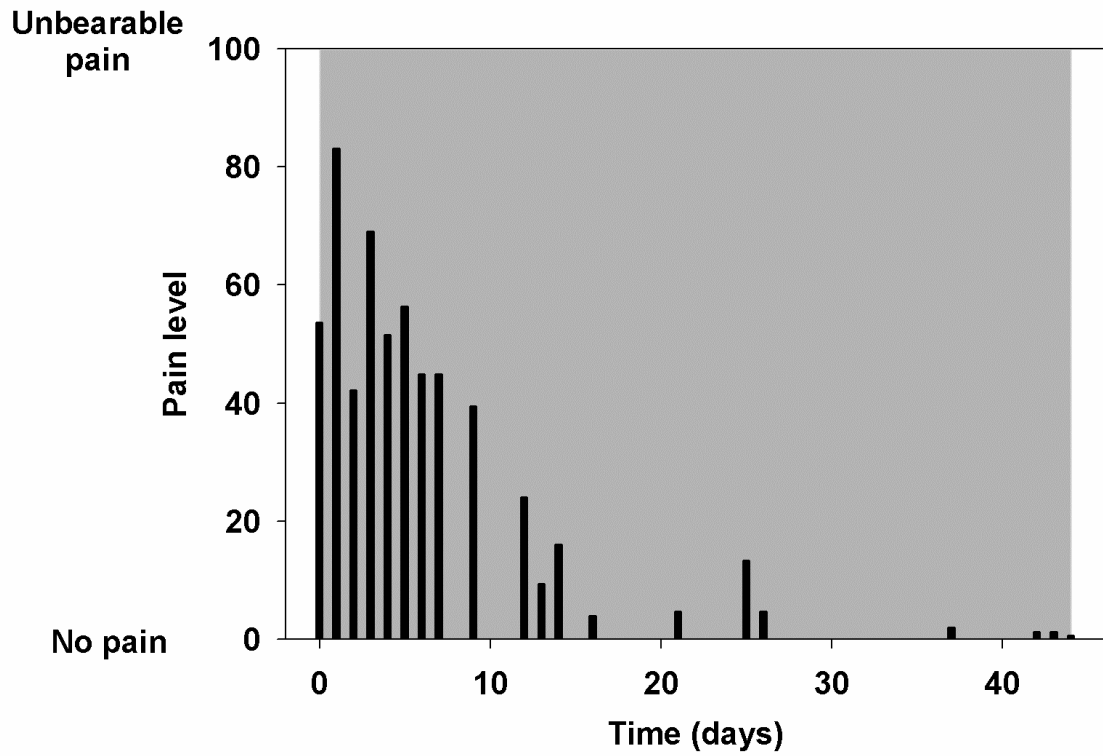
**Ulcer size (patient 6)**



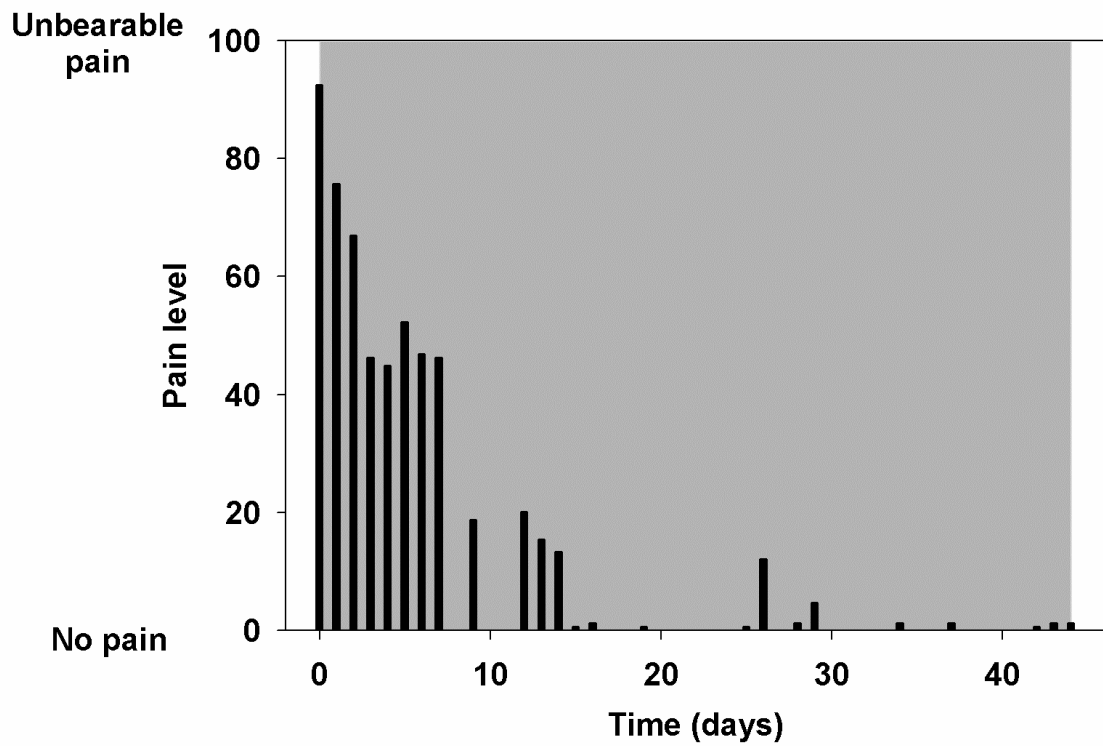
**Pain relief medication (patient 6)**



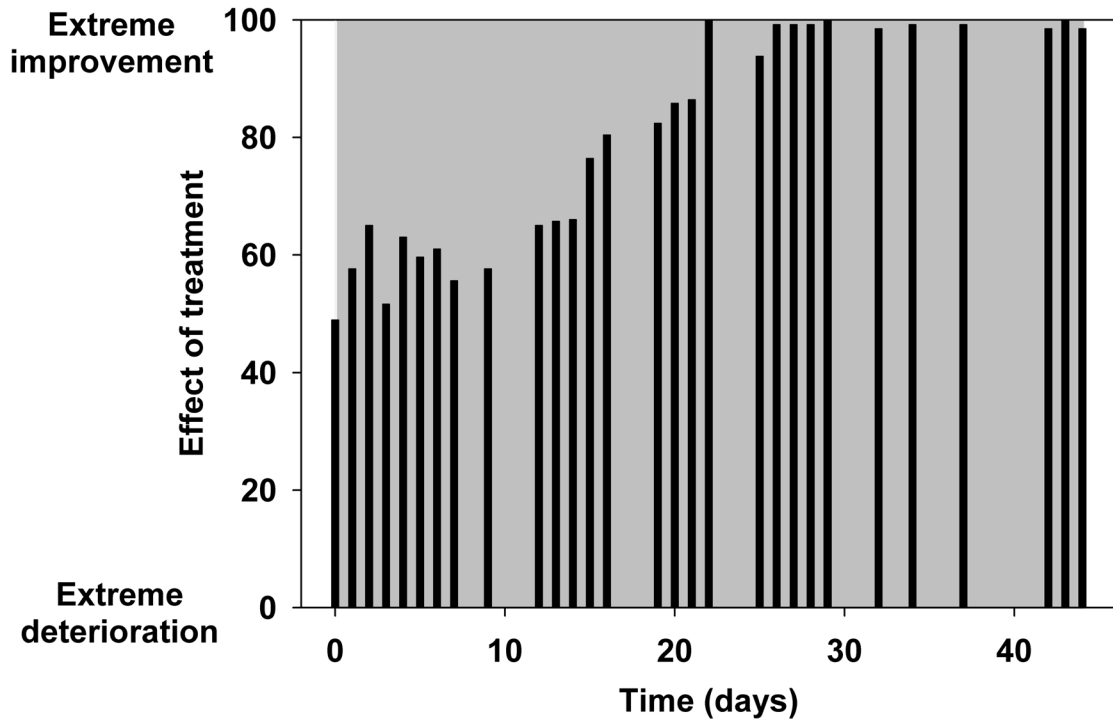
Pain assessment prior to treatment (patient 6)



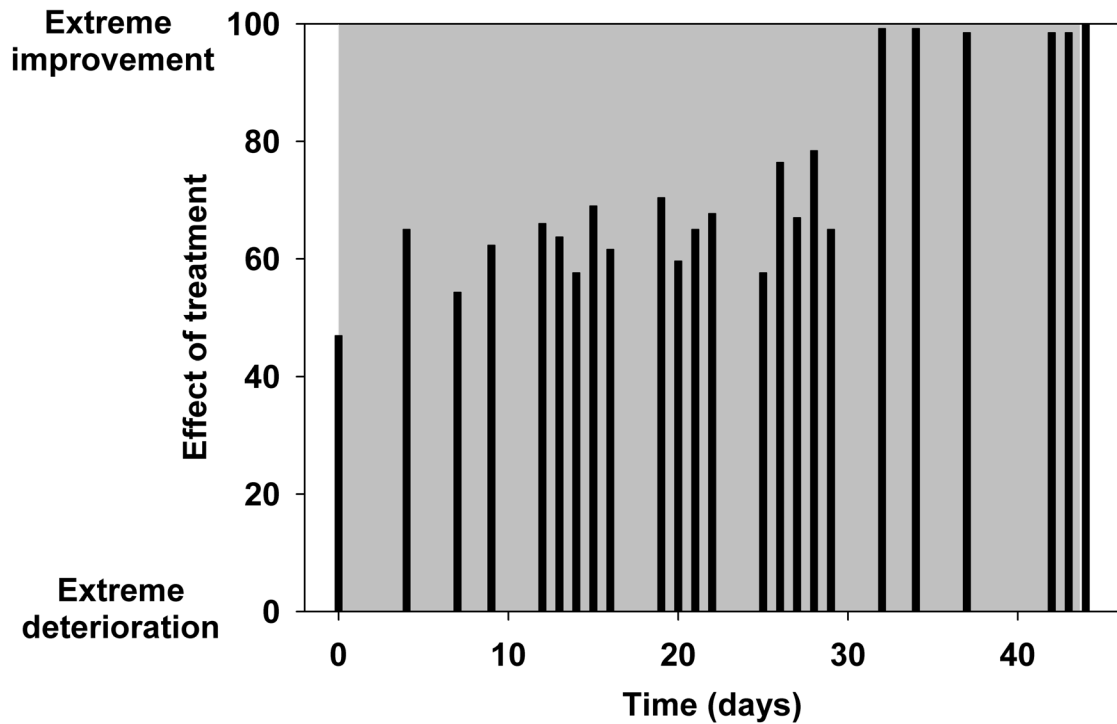
Pain assessment after treatment (patient 6)



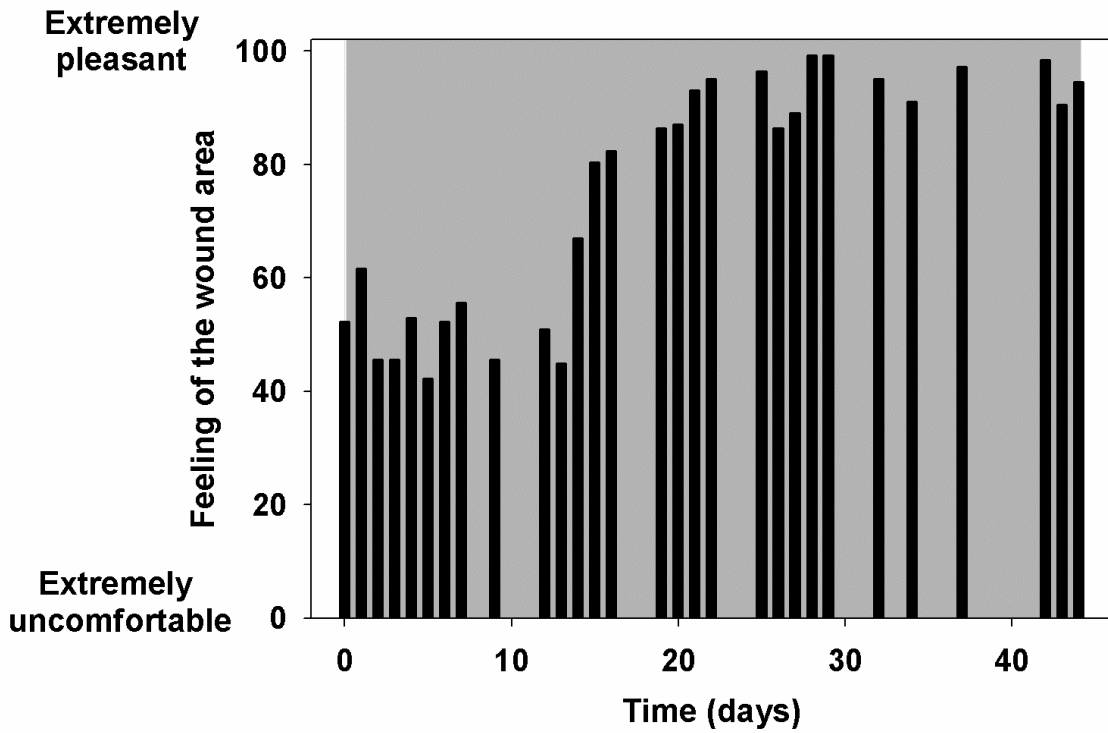
**Effect of treatment (patient 6's assessment)**



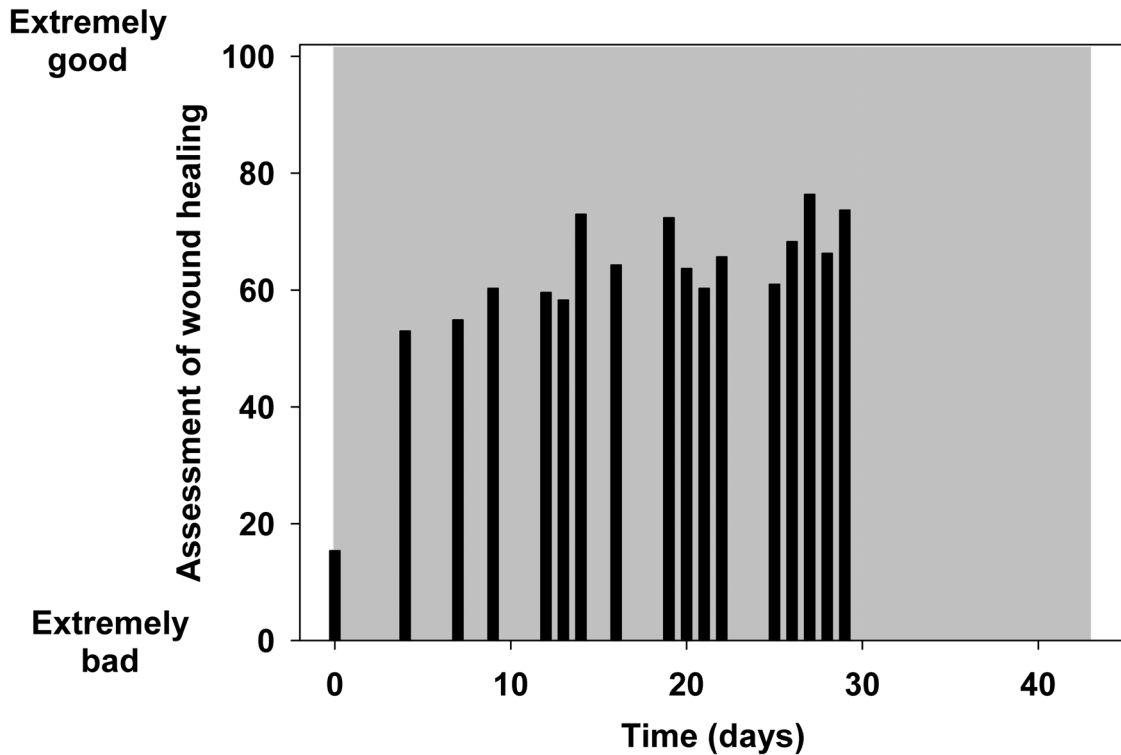
**Effect of treatment (investigator's assessment patient 6)**



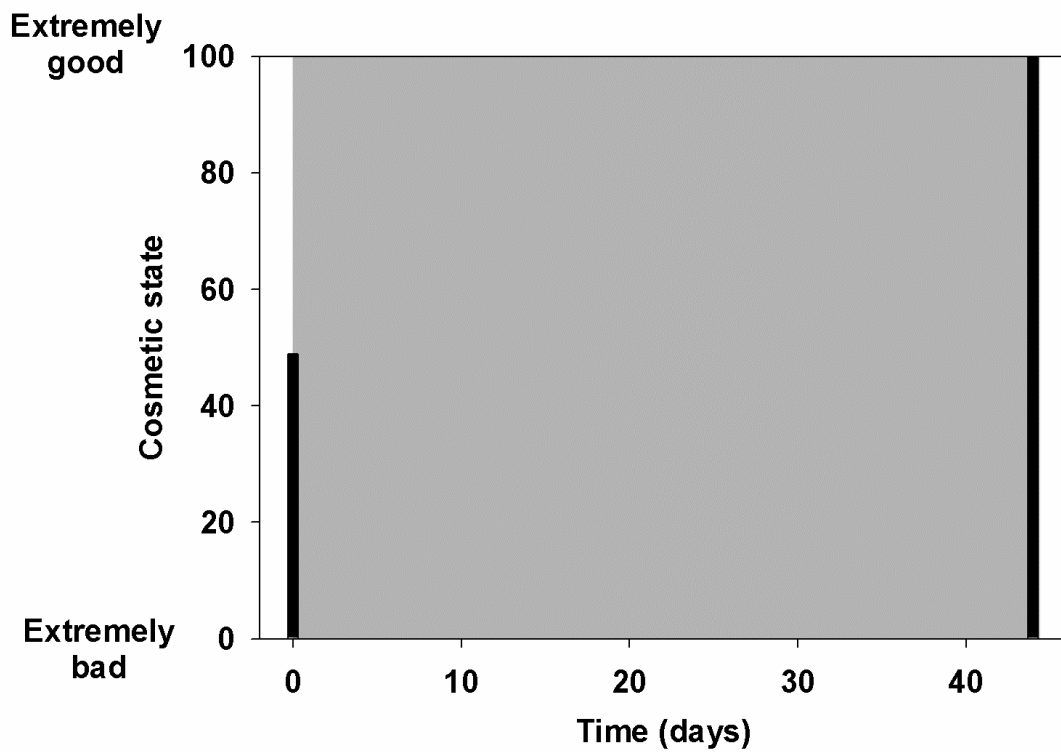
Feeling of the wound area (patient 6's assessment)



Wound healing (investigator's assessment patient 6)



### Cosmetic state (patient 6's assessment)



### Cosmetic state (investigator's assessment patient 6)

