

Appendix 3: Individual Patient Report 3: patient 3: male, 70 years old

First visit November 18, 2002. Patient had single oval shaped ulcer (398 mm²) on the medial malleolar side of the left leg.

Duplex scanning: venous insufficiency at the confluence of the small saphenous vein with the popliteal vein.

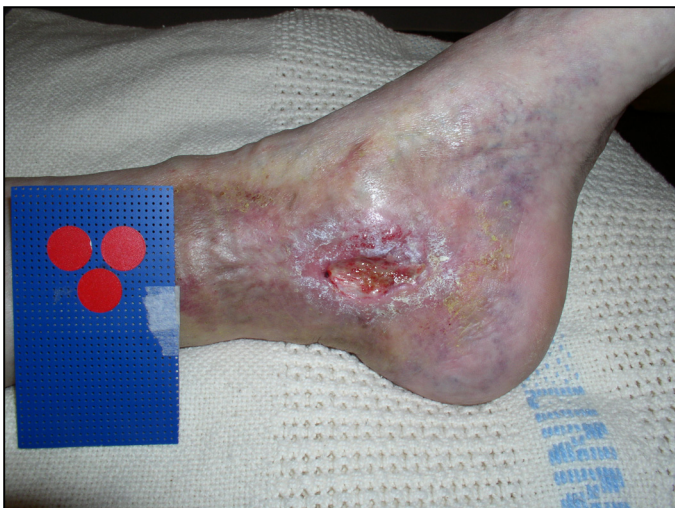Conclusion: venous insufficiency of the left small saphenous vein.

Patient had optimal compression garment therapy (with compression bandages, worn during daytime) all the time between treatments.

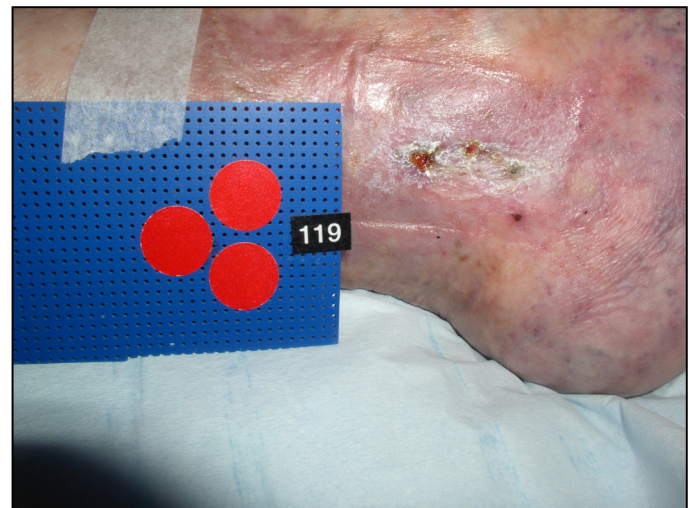
At the end of the treatment period with the wIRA radiator (111 days) the wound had healed. Hereafter the patient underwent surgical resection of the small saphenous vein on March 5, 2004.

This ulcer is classified as a venous ulcer (v) (chronic venous insufficiency stage 3 according to Widmer, which means chronic venous insufficiency with ulcer) without concomitant problems in Table 1 in the results section.

Total number of treatments:	62
First treatment:	2002-11-18
Last treatment:	2003-03-11
Total treatment period:	111 days

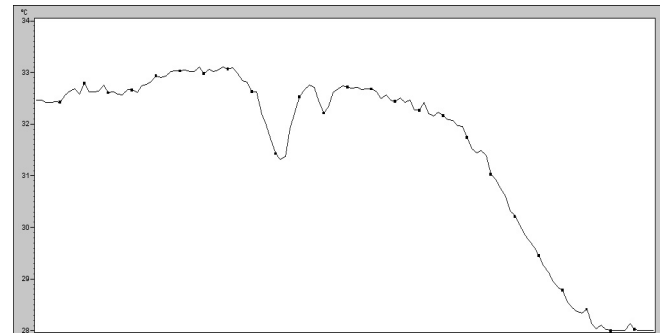
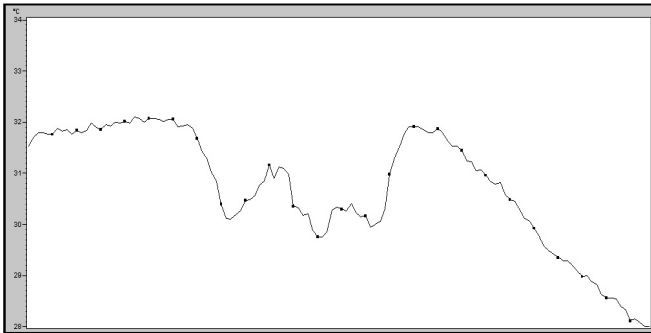
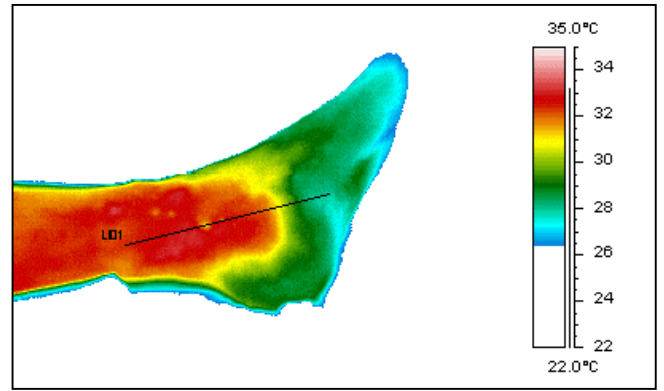
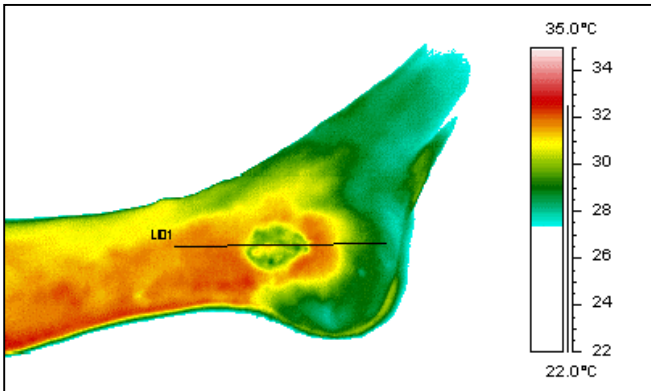


2002-11-18



2003-03-11

Infrared images and temperature profiles through the infrared images

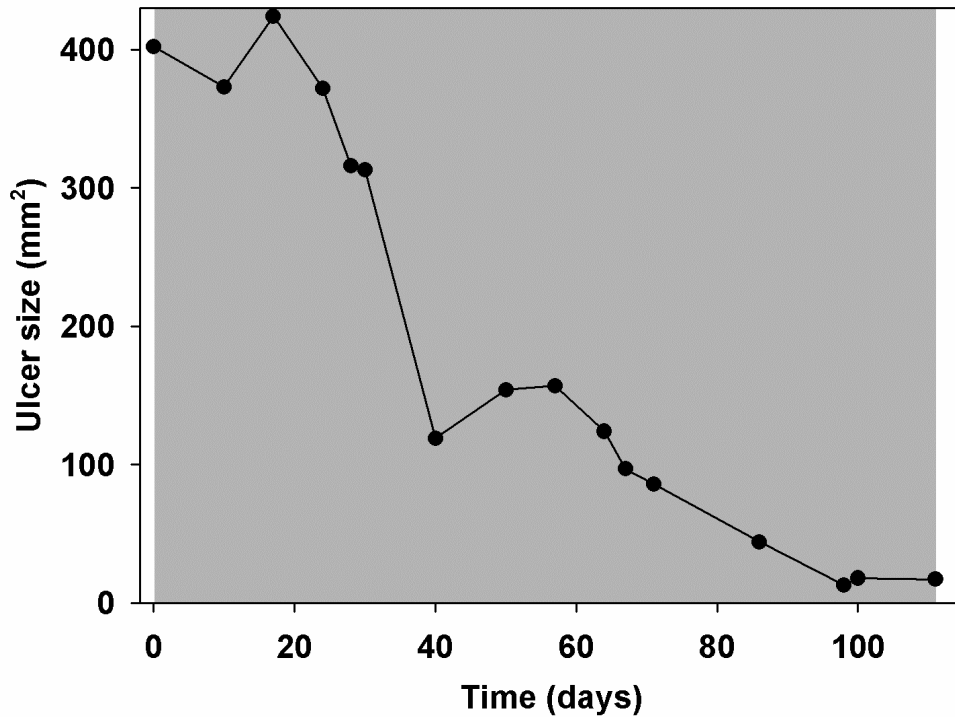


Line analysis		2002-11-18			
Label	Temp.	Min	Max	Avg	Stdev
LI01		28.5	32.1	30.8	1.0

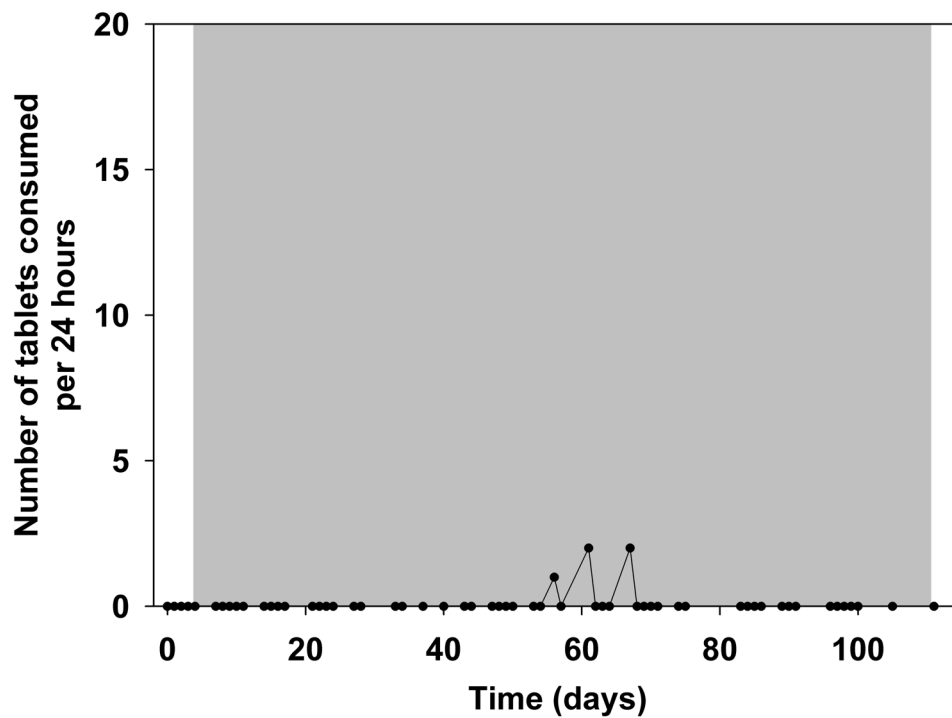
Line analysis		2003-02-28			
Label	Temp.	Min	Max	Avg	Stdev
LI01		27.8	33.1	31.5	1.7

Note: In all figures showing results related to time, the grey shaded area represents the entire wIRA treatment period for this patient (i.e., the total time period between the first and the last treatment).

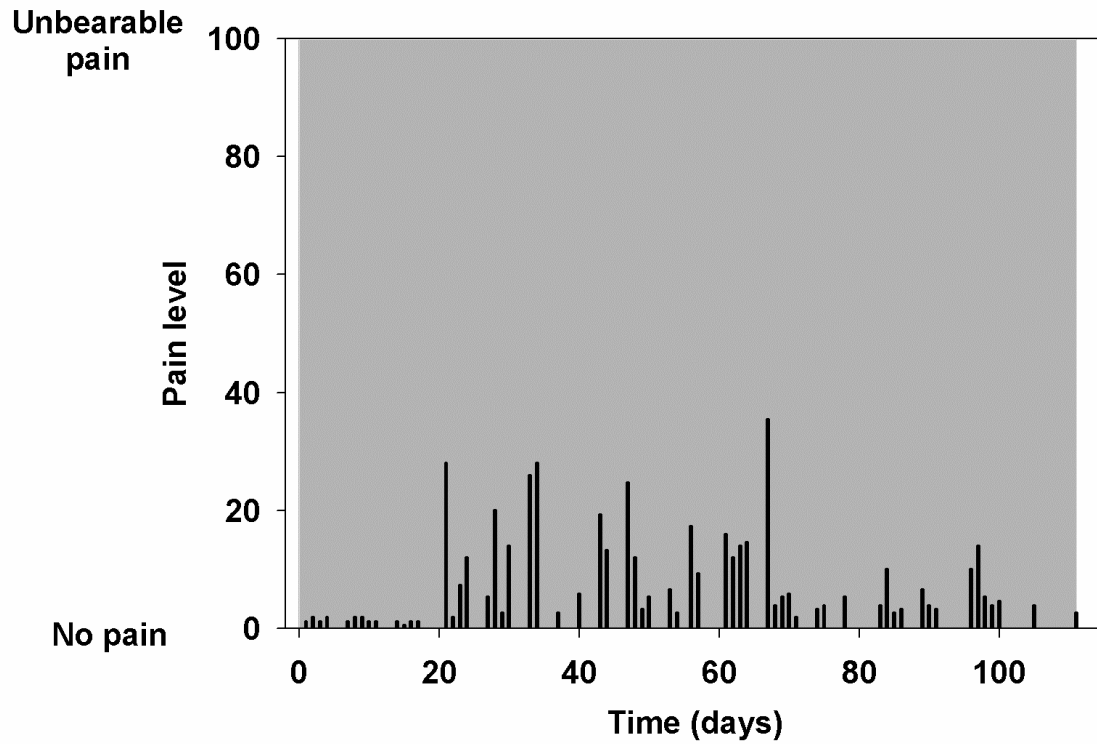
Ulcer size (patient 3)



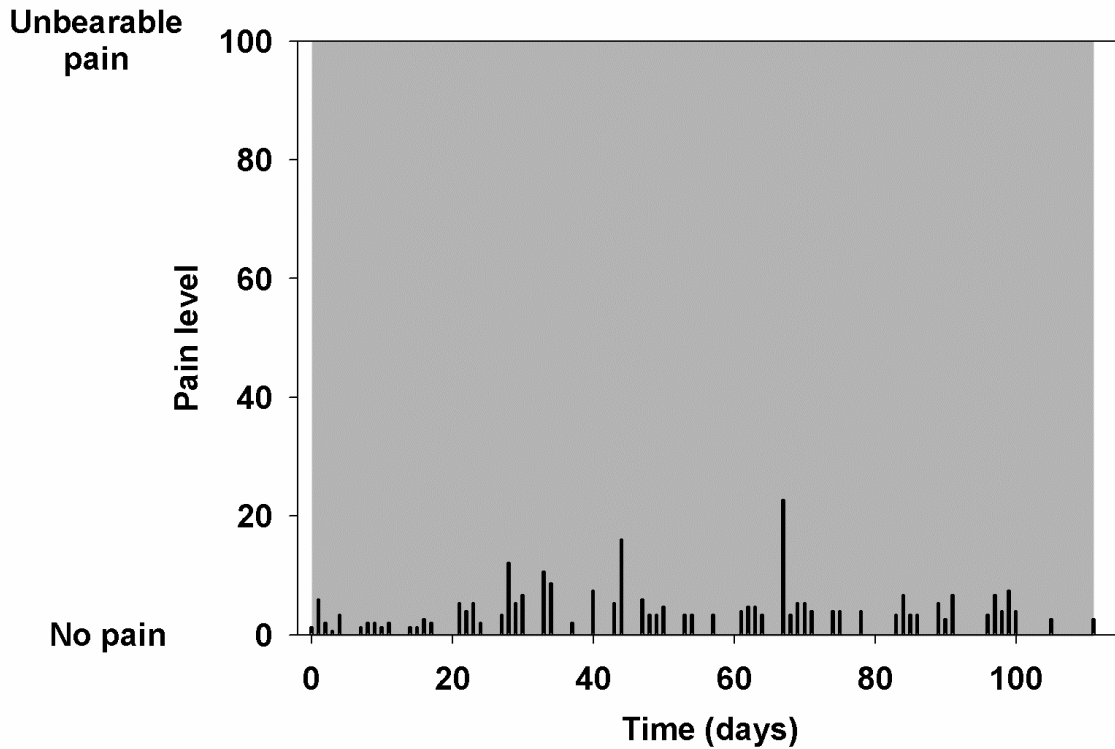
Pain relief medication (patient 3)



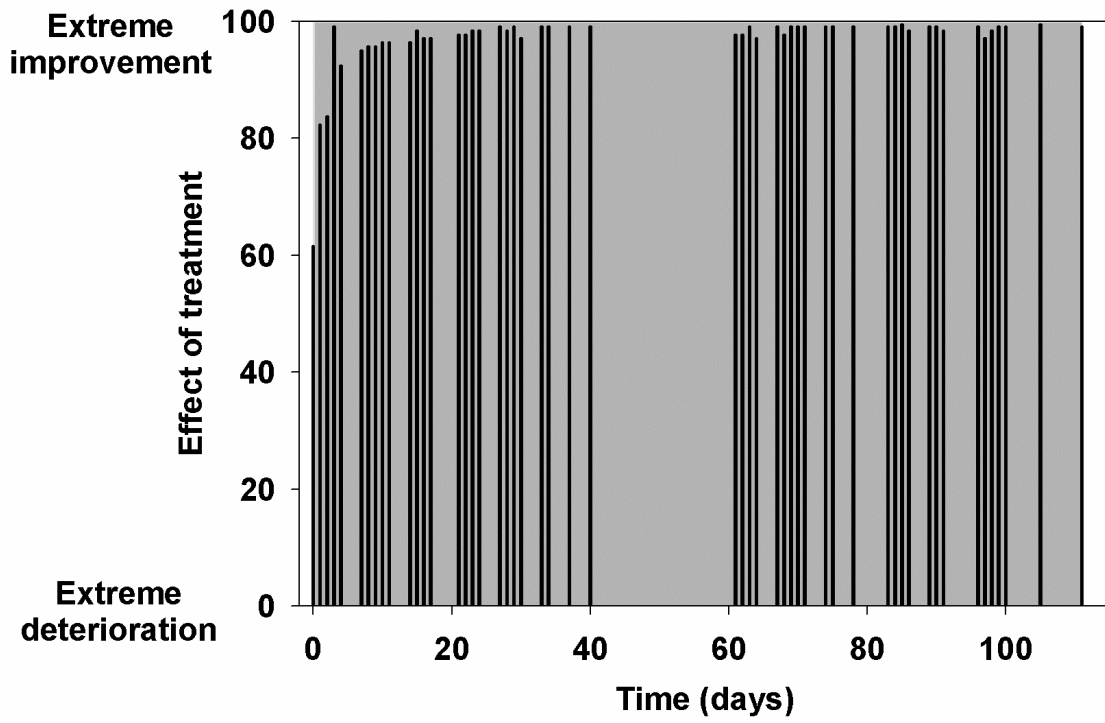
Pain assessment prior to treatment (patient 3)



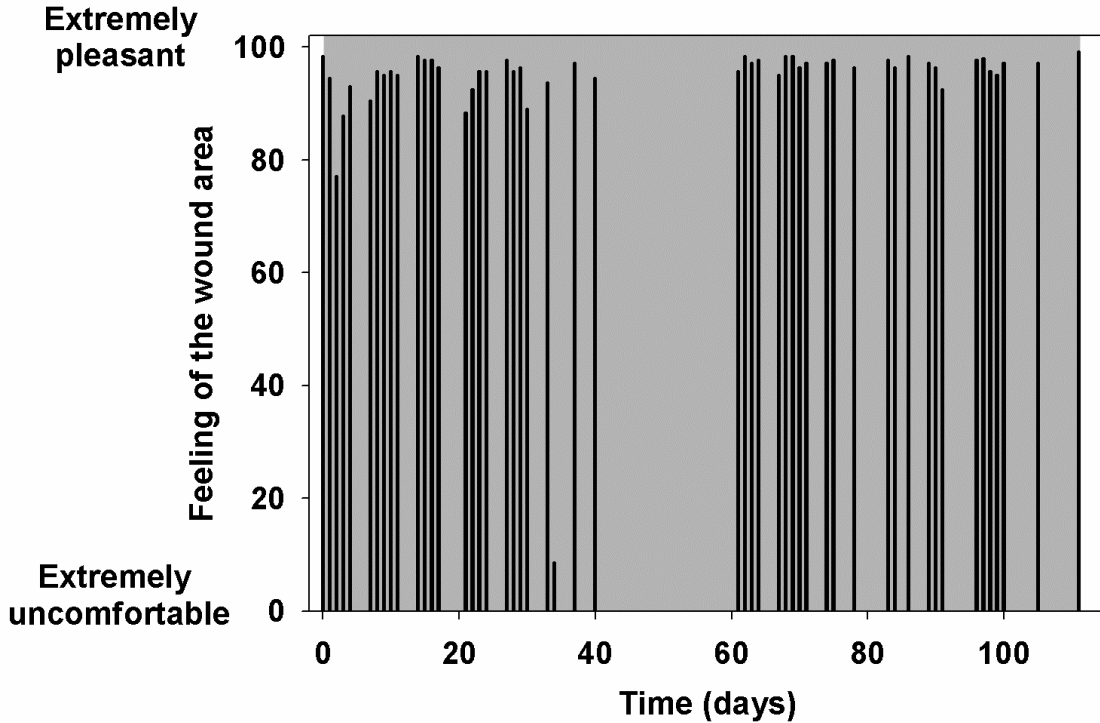
Pain assessment after treatment (patient 3)



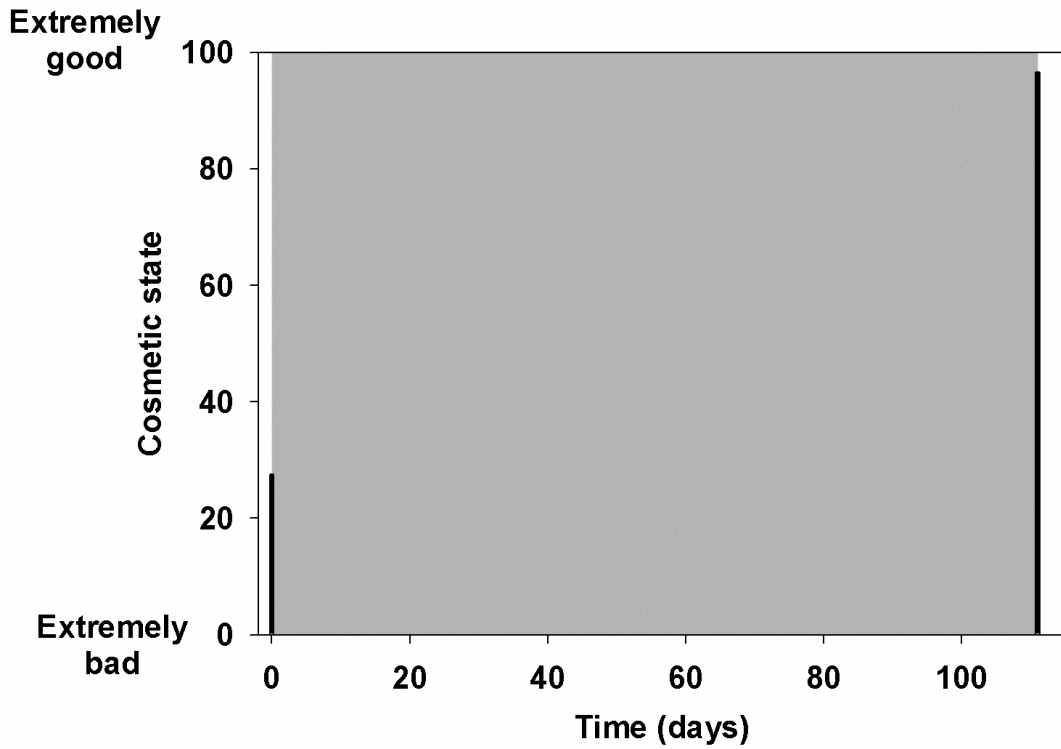
Effect of treatment (patient 3's assessment)



Feeling of the wound area (patient 3's assessment)



Cosmetic state (patient 3's assessment)



Cosmetic state (investigator's assessment patient 3)

